

# Alcian blue as a kidney staining in diabetic mice: An overview after administration of *Loctabacillus plantarum*

*by Sri Sinto Dewi*

---

**Submission date:** 13-Apr-2023 11:27AM (UTC+0700)

**Submission ID:** 2063193082


**File name:** 122-128-Sri\_Sinto.pdf (506.76K)

**Word count:** 3580

**Character count:** 18476



## Original Study

**Alcian blue as a kidney staining in diabetic mice: An overview after administration of *Loctabacillus plantarum***Sri Sinto Dewi<sup>1</sup>, Suci Indah Astuti<sup>1</sup>, Fitri Nuroini<sup>1</sup>, Aprilia Indra Kartika<sup>1</sup><sup>1</sup> Department of Medical Laboratory Technology Universitas Muhammadiyah Semarang, Indonesia

**Abstract:** One of the complications of DM is damage to the kidneys, with oral administration of *L. plantarum*, it can reduce glucose levels so that it is also possible to repair damaged kidney structures. The process of repairing the kidney structure by *L. plantarum* can be seen microscopically in the glomerulus with Alcian Blue staining (AB). The purpose of the study was to determine the differences in the microscopic results of DM rat kidney after treatment of *L. plantarum* with AB staining. The study sample used the kidneys of DM rats. The kidney of DM rats that were given *L. plantarum* at a dose of 1.0 ml/rat in each treatment, T1 (dose 1×1 times a day), T2 (dose 1×2 times a day), T3 (dose 1×3 times a day), then performed AB staining. The results of cytoplasmic cells in the glomerulus in negative controls/sick rat are stained dark blue/concentrated (strong intensity) with a score of 4, normal controls/healthy rat are not stained blue (negative) with a score of 1. T1 is stained light blue score of 3, T2 is stained light blue score of 3, T3 is colored pale blue score of 2. Based on these results, it was found that the color intensity of the AB kidney treatment of DM rats was the best in reducing glucose residues.

**Keyword:** Alcian Blue staining; *Lactobacillus plantarum*; *Diabetes mellitus*

## INTRODUCTION

Type 1 diabetes occurs due to destruction of pancreatic cells (autoimmune reaction)<sup>1,2</sup>. DM caused 1.6 million deaths in 2016, while in 2015 there were 415 million of the number of adults diagnosed with DM, an increase of 4 times from 108 million in 1980, in Southeast Asia in 2014, there were 96 million adults with diabetes in 11 countries<sup>3</sup>. DM is a disease that affects almost all organs of the body, including the heart, blood vessels, eyes, nerves, and kidneys.

Kidneys are excretory organs with a fairly high level of vascularity (Price and Wilson, 2006). Diabetic nephropathy (ND) is a complication that occurs in 40% of all patients with type 1 DM and type 2 DM and is the main cause of kidney disease in patients receiving kidney therapy which is characterized by an increase in blood pressure resulting in decreased glomerular filtration<sup>4</sup>.

The decrease in glomerular filtration is caused by the accumulation of blood glucose residues that accumulate in the glomerular part of the kidneys, with the accumulation of kidney residues causing the organ to be fragile so that the connective tissue that connects cells is also fragile. The conversion of carbohydrates to lipids increases the amount of intracellular glycogen through increased glycogen synthesis, or impaired glycogenolysis causes an increase in glucose, in uncontrolled hyperglycemic conditions, can trigger hyperfiltration and renal hypertrophy resulting in reduced glomerular filtration area. These changes cause impaired kidney function to become glomerulosclerosis<sup>5</sup>.

Corresponding author.

E-mail address: [sintomun@unimus.ac.id](mailto:sintomun@unimus.ac.id) (Sri Sinto Dewi)

DOI: [10.29238/teknolabjournal.v11i2.386](https://doi.org/10.29238/teknolabjournal.v11i2.386)

Received 16 November 2022; Received in revised form 01 December 2022; Accepted 15 December 2022

© 2022 The Authors. Published by [Poltekkes Kemenkes Yogyakarta](http://Poltekkes Kemenkes Yogyakarta), Indonesia.

This is an open-access article under the [CC BY-SA license](https://creativecommons.org/licenses/by-sa/4.0/).

Alcian Blue (AB) is a histochemical stain used to detect carbohydrate content in tissues. Administration of *L. plantarum* can reduce glucose levels so that it is also possible to repair damaged kidney structures in DM patients, which can be seen microscopically with AB staining<sup>6</sup>. *L. plantarum* has the potential to lower blood glucose and create hypoglycaemic conditions. The basic dye in AB is copper phthalocyanin which is soluble in water so it can be blue because of its copper content and has an affinity for acidic tissues, copper compounds carry a positive charge and are attracted to acidic carbohydrates with a negative charge to form a blue color<sup>7</sup>.

This study aims to determine the differences in the microscopic results of the kidneys diabetic rats after treatment using *Lactobacillus plantarum* with AB staining. *Lactobacillus* can be used to lower blood sugar (Okta, 2019). One of the complications of diabetes is nephropathy. AB staining was used to determine whether the kidneys of DM rats treated with *Lactobacillus* had any improvement in kidney tissue. AB has an intensive color discrimination ability in kidney damage due to DM with healthy kidney conditions.

## MATERIAL AND METHOD

The type of research used in this research is experimental. The research design was True experimental design with Post Test-Only Control Group Design method<sup>6</sup>. This study used 25 male Wistar rats aged 12-16 weeks with an average body weight of 150-200 g which were divided into 5 groups and each group contained 5 rats. Group I: No treatment/healthy rats (negative control), Group II: alloxan induced/DM rats (positive control), Group III (T1): DM rats and given *Lactobacillus plantarum* suspension at a doses of 1.0 ml/rat (dose 1 × 1 time a day), Group IV (T2): doses of 1.0 ml/rat (dose 1 × 2 times a day), Group V (T3): doses of 1.0 ml/rat (1×3 dose) times a day). Induction of alloxan monohydrate was performed on test animals intraperitoneally at a dose of 150 mg/kg BW after the adaptation process for 7 days in the laboratory. Diabetic rats fasting blood glucose levels ± 200 mg/dL. Rats that had diabetes were given *Lactobacillus plantarum* isolate from breast milk according to the dose that had been set in each group. Treatment was done orally for 7 days with an interval of 5 hours for *Lactobacillus plantarum*. During the treatment the rats were fed and watered ad libitum. The sample in this study amounted to 25 kidney preparations of DM rats.

The materials (reagents) used in the processing and staining were 9 rat kidneys, 10% BNF, AB staining, Nuclear Fast Red, Alcohol (70%, 80%, 96% and 100%), xylol, paraffin. Tissue samples were fixed with Buffered Neutral Formaldehyde (BNF), 10% BNF volume. The sample was removed from the fixation solution and then the tissue was cut with a size of 1x1 cm. The sample is put into a tissue processor machine, immersed in a tank containing 10% BNF for 2 hours, followed by immersion in a tank containing low to high concentration alcohol, starting from 70%, 80%, 96% (for 1 hour 30 minutes each steps) and absolute alcohol I, II and III for 1 hour each steps. The tissue immersed in a tank containing a solution of xylol I and xylol II for 1 h and 30 min each steps, then the tank was immersed in a tank containing a solution of paraffin I and II for 2 h each steps. The tissue is removed from the tissue processor and then transferred to a microwave oven, the paraffin used for blocking the melting point is the same as the paraffin used for paraffin infiltration. This blocking process is carried out by pouring a small amount of paraffin liquid at a temperature of 60-65°C into the mold. As soon as the tissue is inserted using heated tweezers (so that the paraffin is not frozen) and positioned in the mold, the liquid paraffin is then poured back to cover the entire mold and the mold is left to stand until the paraffin solidifies.

The solid block preparations were cut with a rotary microtome to make slide preparations such as ribbons measuring 3-4 µm. The ribbon formed was placed in a water bath filled with warm water with a temperature of 52° C. The slide preparations were observed under a microscope, if they were good, they were

continued to be dried on a hotplate and ready for staining (Anatomical Pathology Laboratory of RSI Sultan Agung).

The initial stage of staining is by removing paraffin from the preparation (deparaffinization) by immersing it in a solution of xylol I, xylol II for 2-5 min each steps, then giving water to the tissue (rehydration) using an alcohol series graded from 100%, 95% and 70 % each steps for 2-5 min, then washing with distilled water to remove residual alcohol for 2-5 min. The preparations were stained with AB pH 2.5 staining for 30 min, after a bluish color change (positive reaction) occurred, then washed with running water for 5 minutes, then rinsed with distilled water, then dripped with contrast stain (counterstain) using Nuclear Fast Red, then wait for 5 minutes, while looking at it with a microscope. The preparations were washed with distilled water for 2-5 min until clean, then dehydrated from the preparation with 70%, 95%, and 100% alcohol. followed by the clearing process using xylol I and xylol II each for 3 min until they were clear (Anatomical Pathology Laboratory, Moewardi Hospital).

The readings of the preparations were carried out by Anatomical Pathology Specialist. Tissue was observed on microscope with a magnification of 400x in the cytoplasmic cells contained in the glomerulus as many as 50 glomeruli according to the criteria, then the results of the assessment (scoring) were entered into the table of reading results. Data was collected from the reading of kidney tissue preparations with AB staining, all data obtained from the results of the assessment and analyzed by the Kruskal Wallis test.

## RESULTS AND DISCUSSION

The higher intensity doses treatment of *Lactobacillus plantarum* in DM rats, the lower level of blue color in the kidney glomeruli (Table 1). AC staining produces a blue color which indicates the sugar content in the kidneys. Giving *Lactobacillus plantarum* can reduce sugar in the kidneys of DM rats that it can reduce nephropathy. Kidney preparations of DM rats were stained blue using AB staining on the mucin (nephron coating). Mucins are part of epithelial cells composed of glycoproteins (Figure 1a). Mucin is composed of protein in the core and surrounded by carbohydrate chains (80%). AB staining is a large planar phthalocyanine with a copper atom in the center. AB staining contains four basic isothiuronium groups that carry a positive charge. The positive charge exerted by these groups results in the attraction of the AB staining dye molecule to the anionic site in the mucin molecule. AB staining does not color the neutral mucin.

Table 1. Results of Average Color Intensity in Kidneys of DM Rats

Treatment groups	Mean score
Negative control	4
Normal control	1
T1	3
T2	3
T3	2

The use of AB staining to distinguish the sugar content in the renal glomerulus because the reaction of the AB staining solution at pH 2.5 can stain all mucins that are acidic or carboxylated or sulfated. Sugar in the kidney glomerulus will ionize at pH 2.5 to produce anionic groups (COO, SO<sub>3</sub>) so that a blue color is formed. Kidney preparations of DM rats treated with *Lactobacillus plantarum* (Figure 1e) had the same color as the kidneys of normal rats (Figure 1b). The kidneys of DM (T3) rats decreased the sugar content in the kidneys so they were not stained blue by AB staining. The more *Lactobacillus plantarum* was given, the less blue color formed on the kidney preparations, indicating that the sugar content was getting lower (Figure 1 c, d, e). The kidneys of DM treatment 1 rats obtained moderate intensity results with a score of 3 on the preparations. Kidney

preparations in DM treatment 1 mice in the glomerulus there was a lot of accumulation of glucose residues so that the cytoplasmic cells reacted a lot by AB stained light blue. The moderate intensity in treatment 1 was in accordance with the<sup>8</sup> variations of intensity in the AB staining caused by the content of a lot or less accumulation of glucose residues in the glomerulus, which was seen in the cytoplasmic cells in the glomerulus<sup>9</sup>. If the intensity is weak, the cytoplasm of the cell will be colored pale blue.

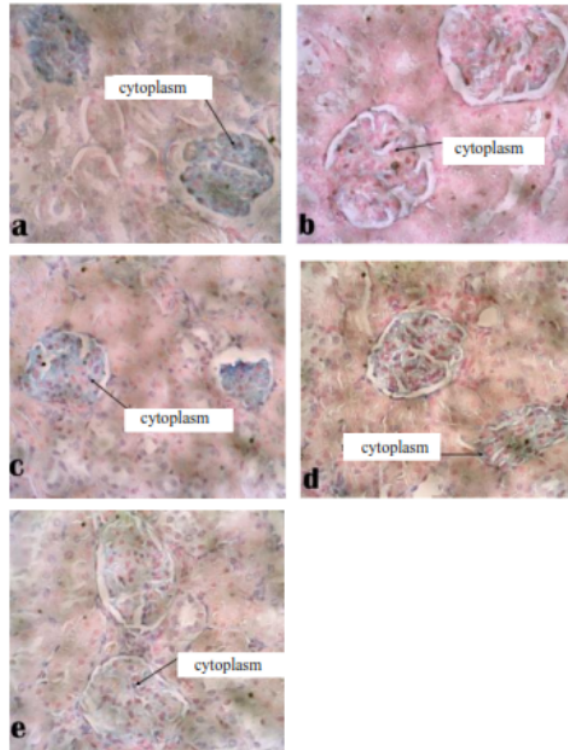


Figure 1. Microscopic results of AB staining at 400x magnification in the kidneys of DM rats at the glomerulus (a) Negative control; (b) Normal control; (c) Treatment 1; (d) Treatment 2; (e) Treatment 3

Treatment 2 obtained moderate intensity results with a score of 3, in the glomerulus there was a lot of accumulation of glucose residues so that the cytoplasmic cells reacted a lot by AB colored light blue. Treatment 3 obtained weak intensity results with a score of 2 on the preparations, in the glomerulus there was a slight accumulation of glucose residues so that the cytoplasmic cells reacted very little by AB stained with pale blue and light blue. Differences in color intensity that vary in the cytoplasm indicate differences in the amount of glucose in the glomerulus<sup>10</sup>. Carbohydrates are scattered in body tissues, these compounds are mainly found on the cell surface, in the cytoplasm (depending on the functional activity of the cell), AB staining pH 2.5 is used to detect mucopolysaccharides that are sour.

The microscopic results of the kidneys of DM with AB mice in this study showed that the treatment groups T1, T2, T3 showed a decrease in blood glucose levels after being given *L. plantarum* isolate from breast milk according to the dose of each treatment group but still above normal. Treatment using *L. plantarum* after the rats had diabetes had a significant effect on the average decrease in the rats' blood glucose levels<sup>6</sup>. *L. plantarum* administered to experimental animals was able

to improve HbA1C by decreasing glucose levels in prediabetic subjects<sup>11</sup>. *L. plantarum* could regulate glucose metabolism in the liver, protect islet beta cells, and restore gut microbiota<sup>12,13,14</sup>. *L. plantarum* has potential as an antihyperglycemic agent. *L. plantarum* recommended for food applications and pharmaceuticals products to prevent diabetes<sup>15,16</sup> because *L. plantarum* has the ability to inhibit the enzyme alpha glucosidase. The alpha glucosidase enzyme is an enzyme that plays a role in the breakdown of carbohydrates into glucose in the digestive tract<sup>17</sup>. The breakdown of carbohydrates into glucose results in higher blood glucose levels in diabetics so that the work of this alpha glucosidase enzyme in the intestine must be inhibited<sup>13</sup>.

All three doses (T1, T2, and T3) had an equivalent glucose-lowering effect. The mean score was found to be of weak intensity at T3, so that the dose given 3 times a day is a good dose in reducing blood glucose efficiently. *Lactobacillus plantarum* identify potent anti-obesogenic and diabetic probiotics. Live probiotic orally in DM mice strongly attenuated weight gain and insulin resistance<sup>18</sup>. Administration of *Lactobacillus* (LAB) to determine the antidiabetic effect in addition to increasing insulin resistance, can also increase the level of expression of glucose transporter 4 (Glut4) and adiponectin genes in epididymic mice tissue. Glut4 and adiponectin are associated with increased insulin action. Upregulation of Glu4 and adiponectin expression is evidence that LAB can be used as an antidiabetic. Long-term research on LAB administration can restore the expression of genes associated with sugar metabolism that can downregulate obesity<sup>12,19,20</sup>. LAB is able to improve the composition of the microbiota in the gut. *Lactobacillus* given to mice can reduce blood sugar and body weight. Giving *Lactobacillus* is able to change the composition of the gut microbiota by suppressing opportunistic bacteria that can cause metabolic diseases<sup>21</sup>.

## CONCLUSION

Microscopic AB staining results based on the mean score on negative controls/sick mice stained dark blue/solid (strong intensity) with a score of 4, normal controls/healthy mice not stained blue (negative) with a score of 1, treatment 1 stained with light blue (medium intensity) with a score of 3, treatment 2 was stained light blue (medium intensity) with a score of 3, treatment 3 was stained pale blue (weak intensity) with a score of 2. Better microscopic results based on the intensity of the color binding to glucose residues were found in treatment 3 with weak intensity.

## ACKNOWLEDGEMENT

We would like to thank the Department of Medical Laboratory Technology D4, the Molecular Biology laboratory team, and the UNIMUS Research and Community Service Institute.

## AUTHOR'S CONTRIBUTION STATEMENT

Sri Sinto Dewi (construction of research ideas, design the research, analyzed data), Suci Indah Astuti (conducting lab-scale research, treating rats, making preparation for kidney tissue). Fitri Nuroini (contributing writing the manuscript), Aprilia Indra Kartika (contributing writing the manuscript).

## FUNDING INFORMATION

-

## DATA AVAILABILITY STATEMENT

The utilized data to contribute to this investigation are available from the corresponding author on reasonable request.

## DISCLOSURE STATEMENT

The views and opinions expressed in this article are those of the authors and do not necessarily reflect the official policy or position of any affiliated agency of the authors. The data is the result of the author's research and has never been published in other journals.

## REFERENCE

1. Dav G, Santilli F, Patrono C. Nutraceuticals in Diabetes and Metabolic Syndrome Diabetes Mellitus and Metabolic Syndrome: Role of Inflammation and Oxidative Stress. *Cardiovasc Ther.* 2010;28:216-226. doi:10.1111/j.1755-5922.2010.00179.x
2. Shin J, Lee J, Lim S, et al. Metabolic syndrome as a predictor of type 2 diabetes, and its clinical interpretations and usefulness. *J Diabetes Investig.* 2013;4(4). doi:10.1111/jdi.12075
3. CDC. *National Diabetes Statistics Report.*; 2020.
4. Sartika F, Purbayanti D, Safitri D. Gambaran laju filtrasi glomerulus pada penderita diabetes mellitus tipe 2 di RSUD DR. Doris Sylvanus Palangkaraya. *J Surya Med.* 2018;3(2):13-21.
5. Sari N, Hisyam B. Hubungan antara diabetes mellitus tipe II dengan kejadian gagal ginjal kronik di Rumah Sakit PKU Muhammadiyah Yogyakarta periode Januari 2011-Oktober 2012. *JKKI.* 2014;6(1):11-18.
6. Kartikasari O, Astuti AD, Berkah M, Wabula M, Dewi SS. Aktivitas *Lactobacillus plantarum* Isolat Air Susu Ibu pada Tikus Galur Wistar Diabetes Mellitus. 2019;10(November):422-429.
7. Doan C. Special Stains-Which One, Why and How? Part 1: Mucins and Glycogen – Leica Biosystems. <https://www.leicabiosystems.com/knowledge-pathway/special-stains-which-one-why-and-how/>.
8. Wahyuni S, Zuchri, Hamny, Jalaluddin M, Adnyane IKM. Studi Histokimia Sebaran Karbohidrat Usus Biawak Air (*Varanus salvator*). *Acta Vet Indones.* 2015;3(2):77-84.
9. Li X, Wang N, Yin B, et al. Effects of *Lactobacillus plantarum* CCFM0236 on hyperglycaemia and insulin resistance in high-fat and streptozotocin-induced type 2 diabetic mice. *J Appl Microbiol.* 2016;121:1727-1736. doi:10.1111/jam.13276
10. Teme ABY, Selan YN, Amalo FA. Gambaran anatomi dan histologi esofagus dan proventrikulus pada ayam hutan merah (*Gallus gallus*) asal Pulau Timor. *J Vet Nusant.* 2019;2(2):85-103.
11. Oh M, Jang H, Lee S, et al. *Lactobacillus plantarum* HAC01 Supplementation Improves Glycemic Control in Prediabetic Subjects: A Randomized, Double-Blind, Placebo-Controlled Trial. *Nutrients.* 2021;13:1-10.
12. Lee Y, Lee D, Park G, et al. *Lactobacillus plantarum* HAC01 ameliorates type 2 diabetes in high-fat diet and streptozotocin-induced diabetic mice in association with modulating the gut microbiota. *food func.* 2021;12:6363-6373. doi:10.1039/d1fo00698c
13. Panwar H, Calderwood D, Grant IR, Grover S, Green BD. *Lactobacillus* strains isolated from infant faeces possess potent inhibitory activity against intestinal alpha- and beta-glucosidases suggesting anti-diabetic potential. *Eur J Nutr.* 2014. doi:10.1007/s00394-013-0649-9
14. Sefidgari-abrasi S, Karimi P, Roshangar L, et al. *Lactobacillus plantarum* And Inulin: Therapeutic Agents to Enhance Cardiac Ob Receptor Expression and Suppress Cardiac Apoptosis in Type 2 Diabetic Rats. 2020:1-14.
15. Zhong H, Zhang Y, Zhao M, et al. Screening of novel potential antidiabetic

- Lactobacillus plantarum strains based on in vitro and in vivo investigations. *LWT - Food Sci Technol*. 2020. doi:10.1016/j.lwt.2020.110526
16. Liu W, Yang M, Wu Y, Chen P, Hsu C, Chen L. Lactobacillus plantarum reverse diabetes- induced Fmo3 and ICAM expression in mice through enteric dysbiosis-related c-Jun NH2- terminal kinase pathways. *PLoS One*. 2018;1-23.
  17. Wardati Y, Deswati DA, Idayati. Uji aktivitas antidiabetes melitus tipe II infus buah kesemek (*Diospyros kaki* Linn.) terhadap tikus jantan putih galur wistar. *Kartika J Ilm Farm*. 2014;2(2):39-44.
  18. Lee E, Jung S-R, Lee S-Y, Lee N-K, Paik H-D, Lim S. Lactobacillus plantarum Strain Ln4 Attenuates Diet-Induced Obesity, Insulin Resistance, and Changes in Hepatic mRNA Levels Associated with Glucose and Lipid Metabolism. *Nutrients*. 2018;10(643). doi:10.3390/nu10050643
  19. Youn HS, Kim J, Lee S, et al. Lactobacillus plantarum Reduces Low-Grade In fl ammation and Glucose Levels in a Mouse Model of Chronic Stress and Diabetes. *Infect Immun*. 2021;89(8):615--620.
  20. Meng X, Qian Y, Kang LJJ. Effects of Lactobacillus plantarum SCS2 on blood glucose level in hyperglycemia mice model. *Appl Biol Chem*. 2016;59(1):143-150. doi:10.1007/s13765-015-0135-6
  21. Gulnaz A, Nadeem J, Han J, et al. Lactobacillus Sps in Reducing the Risk of Diabetes in High-Fat Diet-Induced Diabetic Mice by Modulating the Gut Microbiome and Inhibiting Key Digestive Enzymes Associated with Diabetes. *Biology (Basel)*. 2021;10(348):1-20.



# Alcian blue as a kidney staining in diabetic mice: An overview after administration of *Loctabacillus plantarum*

## ORIGINALITY REPORT

13%

SIMILARITY INDEX

7%

INTERNET SOURCES

9%

PUBLICATIONS

3%

STUDENT PAPERS

## PRIMARY SOURCES

- 1 Joseph Galukeni Kadhila, Louise Pretorius. "CLINICAL LEARNING EXPERIENCES OF NURSING DEGREE STUDENTS AT THE PUBLIC TRAINING HOSPITALS: KHOMAS REGION, NAMIBIA", Research Square Platform LLC, 2022  
Publication 1%
- 2 Submitted to Sheffield Hallam University  
Student Paper 1%
- 3 Hyun Seong Youn, Jong-Hwa Kim, Ji Soo Lee, Yeo Yeong Yoon, Seong Jun Choi, Joo Young Lee, Wonyong Kim, Kwang Woo Hwang. " reduces low-grade inflammation and glucose levels in a mouse model of chronic stress and diabetes ", Infection and Immunity, 2021  
Publication 1%
- 4 conferences.unusa.ac.id  
Internet Source 1%
- 5 oamjms.eu  
Internet Source 1%

6	<a href="http://jurnal.unej.ac.id">jurnal.unej.ac.id</a> Internet Source	1 %
7	A I Kartika, T P Retnani, M S Fitria, A Iswara, A H Mukaromah. "The threat of foodborne disease from raw seafood: isolation and molecular identification of bacteria from the gut of <i>Portunus pelagicus</i> ", IOP Conference Series: Earth and Environmental Science, 2022 Publication	1 %
8	Eris Septiana, Nurul Maulida Rizka, Yadi Yadi, Partomuan Simanjuntak. "Antidiabetic Activity of Extract Combination of <i>Orthosiphon aristatus</i> and <i>Oryza sativa</i> L. var <i>glutinosa</i> ", Borneo Journal of Pharmacy, 2021 Publication	1 %
9	Lou, A. R., K. H. Madsen, O. B. Paulson, H. O. Julian, J. U. Prause, H. R. Siebner, and T. W. Kjaer. "Monocular Visual Deprivation Suppresses Excitability in Adult Human Visual Cortex", Cerebral Cortex, 2011. Publication	1 %
10	<a href="http://www.ncbi.nlm.nih.gov">www.ncbi.nlm.nih.gov</a> Internet Source	1 %
11	D. An. "Role of changes in cardiac metabolism in development of diabetic cardiomyopathy", AJP Heart and Circulatory Physiology, 06/02/2006 Publication	<1 %

---

12

Tri Prasetyorini, Diah Lestari, Aliffiya Anzalinna, Suratun Suratun. "Profile of Serum Creatinine Levels with Creatinine Clearance Test (CCT) of Patients with Type 2 Diabetes Mellitus at Budhi Asih Hospital in 2021", Jurnal Ilmu dan Teknologi Kesehatan, 2022

Publication

<1 %

---

13

[www.prweb.com](http://www.prweb.com)

Internet Source

<1 %

---

14

[www.ejpmr.com](http://www.ejpmr.com)

Internet Source

<1 %

---

15

[orca.cf.ac.uk](http://orca.cf.ac.uk)

Internet Source

<1 %

---

16

[ijpsr.com](http://ijpsr.com)

Internet Source

<1 %

---

17

[www.hindawi.com](http://www.hindawi.com)

Internet Source

<1 %

---

18

Bangran Qi, Daoyuan Ren, Ting Li, Pengfei Niu, Xiangnan Zhang, Xingbin Yang, Jianbo Xiao. "Fu Brick Tea Manages HFD/STZ-Induced Type 2 Diabetes by Regulating the Gut Microbiota and Activating the IRS1/PI3K/Akt Signaling Pathway", Journal of Agricultural and Food Chemistry, 2022

Publication

<1 %

---

19

Budi Santosa, Herlisa Anggraini, Ika Dyah Mawarni, Niza Muliaturun, Ardiansyah Nugroho, Uly Syarah, Siti Atika Risqoeni. "Erythrocyte index of residents exposed to lead in Tambaklorok, Semarang, Indonesia", Jurnal Teknologi Laboratorium, 2020

Publication

&lt;1 %

20

Dian Masyitha, Lena Maulidar, Zainuddin Zainuddin, Muhammad N. Salim, Dwinna Aliza, Fadli A. Gani, Rusli Rusli. "Histology of Watersnake (Enhydris Enhydris) Digestive System", E3S Web of Conferences, 2020

Publication

&lt;1 %

21

Hao Zhong, Abdullah, Yipeng Zhang, Minjie Zhao, Junhui Zhang, Hui Zhang, Yuhang Xi, Haiying Cai, Fengqin Feng. "Screening of novel potential antidiabetic Lactobacillus plantarum strains based on in vitro and in vivo investigations", LWT, 2021

Publication

&lt;1 %

22

[garuda.kemdikbud.go.id](http://garuda.kemdikbud.go.id)

Internet Source

&lt;1 %

23

Aneela Gulnaz, Jawad Nadeem, Jong-Hun Han, Lee-Ching Lew, Jae-Dong Son, Yong-Ha Park, Irfan A. Rather, Yan-Yan Hor. "Lactobacillus Sps in Reducing the Risk of Diabetes in High-Fat Diet-Induced Diabetic Mice by Modulating the Gut Microbiome and Inhibiting Key

&lt;1 %

# Digestive Enzymes Associated with Diabetes", Biology, 2021

Publication

---

---

Exclude quotes      Off

Exclude matches      Off

Exclude bibliography      On