

Anterior Uveitis with Complicated Cataract

by Felisa Nur Khayana

Submission date: 13-Sep-2022 09:10AM (UTC+0700)

Submission ID: 1898476797

File name: Felisa_Nur_Khayana_-_Full_text_130922.docx (264.31K)

Word count: 1714

Character count: 9676

Anterior Uveitis with Complicated Cataract

Wahju Ratna Martiningsih*, Andra Novitasari*, Salsabela Afifah Rafaditya**,
Azizah Rifka Ayundanda**, Felisa Nur Khayana **, Dwi Hali Hanggara Putra**

* Ophthalmology Department, Faculty of Medicine, Muhammadiyah Semarang Univeristy, Indonesia

** Student, Faculty of Medicine, Muhammadiyah Semarang Univeristy,

Abstract

Anterior uveitis is inflammation of the iris and ciliary body. Anterior uveitis can lead the complications such as secondary glaucoma and complicated cataracts. Cataract is a common complication in patients with uveitis which is the main cause of blindness in these patients. The patient is A 58-years-old with complaints of blurred vision in both eyes since 1 week ago, and others complaints like red eyes, watery, pain, and glare when exposed to light. The complaints continuously and interfere with the patient's activities. There's nothing to relieve the complaints. The history of missing teeth was recognized, post odontectomy teeth 1.8, 2.8, 3.8, 4.8. History of toothache, since 1 month. On physical examination, visual acuity in the right eye was 20/60 and the left eye was 20/20. Examination of the anterior segment with slit lamp, both eyes had injections, keratic precipitate on the cornea, COA looked cloudy and there was a tyndal effect, the iris showed posterior synechiae, on the lens it looked cloudy. Based on the history and physical examination, the patient was diagnosed with Oculi Dextra Sinistra Anterior Uveitis with Complicated Cataract. In this case, treated with topical steroids 5x1 drops, methylprednisolone 8 mg 2x1, and antacids 2x1.

Keywords: anterior uveitis, cataract, compliactions

2

Introduction

Uveitis is an inflammation of the uvea, which includes the iris, ciliary body, and choroid. Although uveitis is not common, it can, but it can causes the serious problems and even blindness.¹

Based on the etiology, anterior uveitis can be caused by the infectious and non-infectious diseases. Infections that cause anterior uveitis include tuberculosis, syphilis, herpes simplex virus (HSV), varicella zoster virus (VZV). Non-infectious diseases that can cause uveitis is autoimmune, such as spondyloarthropathies, juvenile idiopathic arthritis, uveitis Fuchs syndrome, ulcerative colitis and Whipple's disease.²

In developing countries the common form of uveitis is idiopathic anterior uveitis and is usually caused by infection with herpes and toxoplasmosis is 30-60%. Meanwhile, in developed countries, 25-50% of uveitis is caused by systemic disease and causes non-infectious uveitis.³ The most common cause of uveitis in Indonesia is infection (33%) with the main causes being toxoplasmosis (19%) and tuberculosis (8 %).⁴

Cataract is a common complication in patients with uveitis which is the main cause of blindness in these patients. Cataracts can occur

in 50%-70% of uveitis patients. Complicated cataracts occur as a result of a thickened lens capsule due to posterior synechiae or the changes of the membrane permeability.⁵

Case study

A 58-years-old housewife came to hospital on August 25, 2022 with complaints of blurred vision in both eyes since 1 week ago, and the others complaints like red eyes, watery, pain, and glare when exposed to light. The complaints continuously and interfere with the patient's activities. There's nothing to relieve the complaints. The history of missing teeth was recognized, post odontectomy teeth 1.8, 2.8, 3.8, 4.8. History of toothache, since 1 month.

On physical examination, visual acuity in the right eye was 20/60 and the left eye was 20/20. Examination of the anterior segment with slit lamp, both eyes had injections, keratic precipitate on the cornea, COA looked cloudy and there was a tyndal effect, the iris showed posterior synechiae, on the lens it looked cloudy.

Based on the history and physical examination, the patient was diagnosed with Oculi Dextra Sinistra Anterior Uveitis with Complicated Cataract. The patient treated with topical steroids 5x1 drops, methylprednisolone 8 mg 2x1, and antacids 2x1.

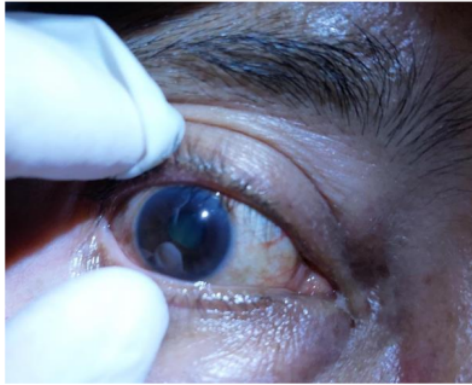


Figure 1. Examination on August 25, 2022 in the right eye with complicated anterior uveitis

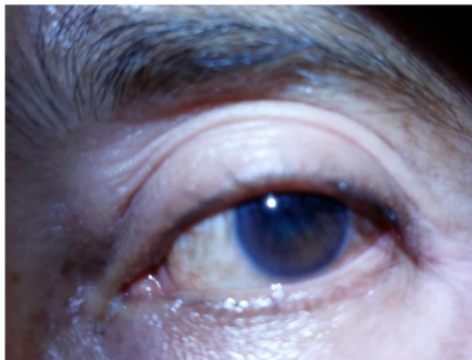


Figure 2. Examination on August 25, 2022 in the left eye with complicated anterior uveitis

The patient returned on August 31, 2022 for control with complaints of blurry eye¹ but getting better. On physical examination, visual acuity in the right eye was 20/40 and the left eye was 20/20. Examination of the anterior segment with a slit lamp showed minimal injection in both eyes, the COA looked cloudy, the iris showed posterior synechiae, and the lens looked cloudy. In management, the therapeutic dose was reduced with topical steroids 3x1 drops, methylprednisolone 4 mg 2x1, and antacids 2x1.

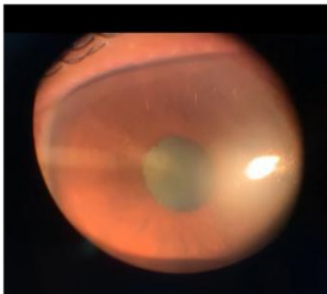


Figure 3. Slitlamp examination on August 31, 2022 in the right eye is anterior uveitis with complicated cataract after one week of therapy

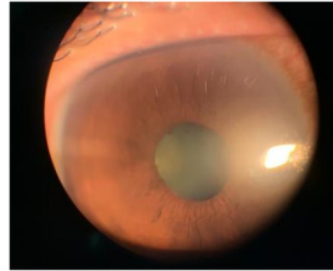


Figure 4. Slitlamp examination on August 31, 2022 in the left eye is anterior uveitis with complicated cataract after one week of therapy

Discussion

² Uveitis is inflammation of the uvea. Anterior uveitis is inflammation of the iris and ciliary body. In this case the patient came to the eye polyclinic with complaints of blurred vision in the right eye since about 1 week ago. Initially, the patient said blurred vision in the right eye accompanied by red eyes, watery, pain, and glare when exposed to light. Symptoms of anterior uveitis may include eye redness, pain, photophobia and decreased visual acuity.⁶

Anterior uveitis may produce throbbing pain due to ciliary muscle spasm. Miosis and posterior synechiae that occur in anterior uveitis result from pupillary sphincter spasm. Severe pain may be felt and it is necessary to suspect an increase in eye pressure. Decreased visual acuity occurs due to cloudiness of aqueous humor and corneal edema, although uveitis does not always cause corneal edema.^{7,8}

A sign of acute anterior uveitis is ciliary injection caused by vasodilation of the longus posterior ciliary artery and the⁴ anterior ciliary artery, which supplies blood to the iris and ciliary body. In the anterior chamber of the eye there are inflammatory cells,⁴ protein secretion (cells and flare) and there are inflammatory cell deposits in the corneal endothelium (keratic precipitate). Smooth precipitate keratices are usually the result of non-granulomatous inflammation and rough precipitate keratices are associated with granulomatous inflammation.⁹

Anterior uveitis occurs due to systemic disorders (infection, autoimmune, malignancy), widespread inflammation in the cornea and sclera, trauma, abnormalities in other organs including teeth, and some are idiopathic.⁹ In this case, patient has a history of toothache since the last month.

The process of anterior uveitis can arise from infection of the teeth. The focal dental infection that plays an important role is the intoxication theory which suggests that the process of odontogenic toxemia occurs. The toxin is not only a toxin from microorganisms, but can also occur from the toxin of the periodontium, alveolus, and tooth root cement layers, which are biogenic amines. Immune reactions that work against antigens will also injure cells from the uveal blood vessels and uveitis can occur due to toxic reactions from pathogens in the body.¹⁰

Acute anterior uveitis usually occurs in only one eye, but in chronic conditions both eyes can be involved. Although chronic anterior uveitis is less common and generally asymptomatic, it can lead to complications such as secondary glaucoma and complicated cataracts. Anterior uveitis that occurs in children will increase the complications of strabismus, keratopathy, macular edema, secondary glaucoma, and complicated cataracts that can lead to decreased vision and trigger amblyopia.¹¹

The patient had complications in the form of complicated cataracts. Complicated cataracts that occur due to anterior uveitis can present with a variety of symptoms. The occurrence of cataracts in anterior uveitis is caused by the type and chronicity of the uveitis and the intensity of the inflammatory treatment (corticosteroid use). In addition, exudation of fibrin and inflammatory cells in anterior uveitis will induce the aqueous humor to become cloudy which causes the lens to appear cloudy. Complicated cataracts can also result from a thickened lens capsule due to posterior synechiae or altered membrane permeability.¹²

Treatment of uveitis aims to treat inflammation, improve visual structure and function, treat pain, and photophobia. Topical corticosteroids are given to treat inflammation. While systemic corticosteroids are given in uveitis conditions that cause severe symptoms and in bilateral uveitis. Inappropriate use of corticosteroids can cause increased intraocular pressure so that glaucoma can occur, cause complicated cataracts, and increase the risk of bacterial and fungal infections when used in the long term, so the use of corticosteroids should be monitored. Corticosteroids given should be lowered slowly to avoid withdrawal syndrome.¹¹

Cycloplegic administration aims to prevent posterior synechiae. In addition, cycloplegic administration aims to rest the eye and release posterior synechiae. NSAIDs are given to treat pain. Antimicrobials are given if uveitis is caused by infection.¹¹ In uveitis due to bacterial infection, antibiotics are given for 2-3 days, after which corticosteroids can be added to suppress inflammation. Focal infection in uveitis must be treated comprehensively to prevent worsening, complications and blindness.¹¹

Surgical therapy is indicated to improve vision. Surgery can be performed on uveitis patients who have calmed down, but are experiencing permanent changes due to complications such as cataracts, secondary glaucoma and retinal detachment. Iris pathological abnormalities such as posterior synechiae, iris vascular fragility, and damage to the blood barrier with aqueous humor make it a challenge for doctors to perform surgery on cataracts with uveitis.⁶

The management that can be given to the patient according to the above case is the administration of cycloplegics which aims to rest the eyes, prevent posterior synechiae, and release posterior synechiae. Steroids can be given for anti-inflammatory, In addition, antibiotics can

also be given which aims to treat infections caused by bacteria. Oral steroids may be used in cases of recurrent anterior uveitis, where topical steroids produce a poor response. H2-receptor blockers such as antacids can be given to prevent the side effects of steroid administration by reducing the production of gastric acid.

In this case, education can be given in the form of wearing sunglasses to prevent glare and watery, avoid rubbing the eyes to avoid infection, avoid using contact lenses, when riding a motorcycle always cover the helmet glass, eat nutritious food, and get enough rest to increase endurance.

Conclusion

Uveitis is one of the leading causes of blindness in developing countries. Management of uveitis aims to suppress the inflammatory reaction, improve the structure and function of vision, relieve pain and photophobia. Drugs that can be used are corticosteroids, immunosuppressants, NSAIDs, cycloplegics and antimicrobials if there is an infection. The underlying disease of uveitis must be treated comprehensively to prevent deterioration and complications.

Anterior Uveitis with Complicated Cataract

ORIGINALITY REPORT

7%

SIMILARITY INDEX

6%

INTERNET SOURCES

5%

PUBLICATIONS

2%

STUDENT PAPERS

PRIMARY SOURCES

1	docksci.com Internet Source	3%
2	Submitted to University of New South Wales Student Paper	2%
3	archive.org Internet Source	1%
4	Yu. "Apoptosis of CD4+ T cells occurs in experimental autoimmune anterior uveitis (EAAU)", Clinical & Experimental Immunology, 12/1999 Publication	1%
5	www.igi-global.com Internet Source	1%
6	Moorthy, R.S.. "Glaucoma associated with uveitis", Survey of Ophthalmology, 199703/04 Publication	<1%

Exclude quotes Off

Exclude matches Off

Exclude bibliography On

