

# Phacolytic Glaucoma

*by* Arfa Raynalda

---

**Submission date:** 09-Sep-2022 04:26PM (UTC+0700)

**Submission ID:** 1895781740

**File name:** Arfa\_Raynalda\_Full\_text\_090922.docx (321.72K)

**Word count:** 1477

**Character count:** 8182

# Phacolytic Glaucoma

Wahju Ratna Martiningsih\*, Andra Novitasari\*, Arfa Raynalda\*\*, Zulfa Jihan Adani\*\*, Hadistya Hakimia Sekh \*\*, Linia Nitrika\*\*

\* Ophthalmology Department, Faculty of Medicine, Muhammadiyah Semarang Univeristy, Indonesia

\*\* Student, Faculty of Medicine, Muhammadiyah Semarang Univeristy, Indonesia

## Abstract

Lens-induced glaucoma can result from both immature and hypermature senile cataracts. Phacolytic glaucoma is caused by leakage of high-molecular-weight proteins through the capsule of a hypermature cataract. The patient is a 74 year old male, with red left eye since 2 days ago. Complaints appear suddenly and persist throughout the day so that it interferes with the patient's activities. Complaints accompanied by a feeling of tingling, watery eyes and headaches. Nothing mitigates the complaint. History of blurred vision such as seeing fog was recognized in both eyes since 1 year ago. On physical examination, visual acuity in the right eye was 20/60 and the left eye was 1/~ poor LP. Examination of the anterior segment with slit lamp, left eye obtained mixed injection, minimal corneal edema, deep COA, dilated pupil, pupillary reflex (-), evenly cloudy lens, iris shadow (-). Digital assessment of intraocular pressure Schioetz 26.6 mmHg. Management of the patients can be given xytrol ED 3x1 drops OS, timolol maleate 0.5% ED 3x1 drops OS, Acetazolamide 1x250mg, aspar K 1x1. Cataract extraction is planned.

Keyword : Cataract, Phacolytic Glaucoma

## Introduction

Lens-induced glaucoma is secondary glaucoma where as a pathogen, either due to an increase in thickness, thereby altering or by an inflammatory process causing an increase in intraocular pressure (IOP).<sup>1</sup>

Phacolytic glaucoma is caused by leakage of high-molecular-weight proteins through the capsule of a hypermature cataract. The clinical presentation usually consists of eye pain, visual disturbances and conjunctival hyperemia.<sup>2</sup>

Phacolytic glaucoma is more common in developing countries. No racial/sexual predilection. Phacolytic glaucoma usually occurs in the elderly. Poor socioeconomic status is a condition that causes neglect of symptoms and delays in access to health services.<sup>3</sup> One study from Nepal diagnosed phacolytic glaucoma in 0.4% of cataract patients.<sup>4</sup> From the University Sains Malaysia study of thirty-eight patients (38 eyes) with lens-induced glaucoma. The mean age was 70.2 years and the majority occurred in women (57.9%).<sup>5</sup>

## Case study

A 74 years old male farmer presented to the Hospital on September 3, 2022 with red, watery, and tingling left eye. Complaints appear

suddenly and persist throughout the day so that it interferes with the patient's activities. Complaints accompanied by headaches. Nothing mitigates the complaint. History of blurred vision such as seeing fog was recognized in both eyes since 1 year ago.

On physical examination, visual acuity in the right eye was 20/60 and the left eye was 1/~ poor light projection Examination of the anterior segment with slit lamp, left eye obtained mixed injection, minimal corneal edema, deep COA, dilated pupil, pupillary reflex (-), evenly cloudy lens, iris shadow (-). Digital assessment of intraocular pressure Schioetz 26.6 mmHg.

Based on the history and physical examination, the patient was diagnosed with Oculi Sinistra Phacolytic Glaucoma et causa Hypermature senile cataract. He was treated with xytrol ED 3x1 drops OS, timolol maleate 0.5% ED 3x1 drops OS, Acetazolamide 1x250mg aspar K 1x1. Cataract extraction is planned.

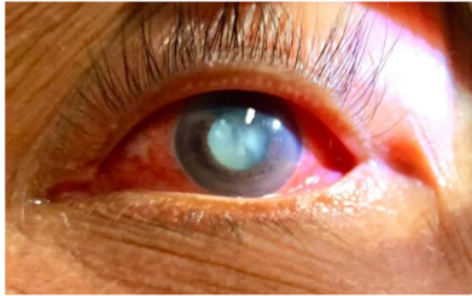


Figure 1. Examination on September 3, 2022 in the left eye with Phacolytic Glaucoma

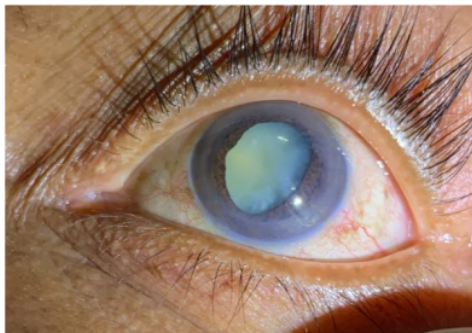


Figure 2. Examination on September 7, 2022 in the left eye with Phacolytic Glaucoma

4 days later, on September 7, 2022 the patient's eye condition improved. On physical examination, visual acuity in the right eye was 20/50 and the left eye was 1/~ good LP. Examination of the anterior segment with slit lamp, left eye found calm anterior segment, deep COA, dilated pupil, pupillary reflex (-), evenly cloudy lens, iris shadow (-). IOP Schiøtz 17.3 mmHg. The treatment was continued and programmed for cataract surgery and IOL insertion.

## Discussion

Phacolytic glaucoma includes lens-induced glaucoma. It is caused by leakage of molecular weight proteins through the capsule of the hypermature cataract. In this case the patient came to the eye polyclinic of Roemani Hospital Semarang with complaints of red eyes since 2 days ago. Complaints accompanied by a feeling of tingling, watery eyes, and headaches. History of blurred vision such as seeing fog was recognized in both eyes since 1 year ago. Symptoms of phacolytic glaucoma can include eye pain, decreased vision and conjunctival hyperemia.<sup>1</sup>

Patients usually present with severe pain, red eyes, blurred vision, and a history of decreased vision for months to years. This decrease in vision occurs due to cataracts, but there is an

acute decrease because there is corneal edema associated with the glaucoma. On examination, the ocular pressure is very high. Microcytic edema may be present on the cornea and there may be scattered cells on the endothelium.<sup>6</sup>

The definitive treatment is surgery to extract the cataract. Prior to surgery, intraocular pressure and inflammation need to be reduced with glaucoma medications and anti-inflammatory corticosteroids.<sup>7</sup>

Beta adrenergic blockers are drugs used to treat glaucoma because they suppress the formation of aqueous humor. The main contraindications to the use of these drugs are chronic obstructive airways disease, especially asthma and cardiac conduction defects. Pilocarpine 2% or 4% is used as a potent miotic and also reduces intraocular pressure by increasing the outflow of aqueous humor by acting on the trabecular meshwork via contraction of the ciliary muscle. Given every 15 minutes up to 4 times as initial therapy, is indicated to try to prevent the onset of acute glaucoma. Pilocarpine is given one drop every 30 minutes for 1-2 hours. In general, the pupillary response is negative to long-standing attacks, causing sphincter muscle atrophy due to ischemia

Another intraocular pressure lowering agent used is the carbonic anhydrase inhibitor, namely acetazolamide. Acetazolamide is an excellent choice for emergency treatment of acute glaucoma. The effect can lower pressure by inhibiting the production of aqueous humor, so it is very useful to reduce intraocular pressure rapidly, can be used orally and intravenously. Acetazolamide with an initial dose of 2x250 mg orally, can be given to patients who do not have gastric complications. An alternative intravenous dose of 500 mg bolus, effective against nausea patients. Increasing the maximum dose of acetazolamide can be given after 4-6 hours to lower the intraocular pressure. Topical carbonic anhydrase inhibitors can be used as initial therapy in patients with emesis.<sup>7</sup> The side effect of acetazolamide is hypokalemia which can result in tetany, paresthesias, kidney stones, and depression so that aspar K supplements are given to avoid hypokalemia.<sup>8</sup>

Osmotic agents are agents for lowering intraocular pressure by turning the blood into hypertonic so that water is drawn out of the vitreous and reduces vitreous volume. Substances that can be used include glycerin, mannitol and intravenous urea. Mannitol is a strong oral osmotic diuretic that can provide benefits and is safe for use in diabetic patients because it is not metabolized. The recommended dose is 1-2

g/KgBW in 50% fluids. The peak of the ocular hypotensive effect is seen in 1-3 hours and lasts in 3-5 hours. If gastric intolerance and nausea can be given intravenously in 20% fluids at a dose of 2 g / kg for 30 minutes. Mannitol with a high molecular weight, will penetrate the eye more slowly so it is more effective in lowering intraocular pressure. Maximum pressure drop is found within 1 hour after intravenous mannitol administration

In this case, the patient was treated with timolol maleate 0.5% as a beta adrenergic blocker which is used to treat glaucoma because it suppresses the formation of aqueous humor. Acetazolamide 1x250mg, as another intraocular pressure lowering agent used is carbonic anhydrase inhibitor. Administration of aspar K to prevent hypokalemia. Giving xytrol eyedrop as an anti-inflammatory steroid can have a good effect on inflammation because it can reduce blood vessel permeability and reduce inflammation symptoms.<sup>9</sup>

In this case, education can be given in the form of conveying that the patient's red eyes, tingling, and decreased vision are due to clouding of the lens which causes increased eye pressure. Explain to the patient that the initial therapy is to control eye pressure and after it is controlled, cataracts will be removed through surgery by an ophthalmologist. Perform routine examination of the right eye. Explain to the patient to reduce strenuous work and stress. Explain to maintain body hygiene, including not touching and wiping.

### **Conclusion**

Lens-induced glaucoma is secondary glaucoma in which phacolytic glaucoma is caused by leakage of molecular weight proteins through the capsule of the hypermature cataract. The definitive treatment is surgery to extract the cataract. Prior to surgery, intraocular pressure and inflammation need to be reduced with glaucoma medications and anti-inflammatory corticosteroids. The drugs used are beta adrenergic inhibitors to suppress the formation of aqueous humor and carbonic anhydrase inhibitors whose effects can reduce pressure by inhibiting the production of aqueous humor, so it is very useful for rapidly lowering intraocular pressure and anti-inflammatory steroids can have a good effect on inflammation.

# Phacolytic Glaucoma

---

## ORIGINALITY REPORT

---

15%

SIMILARITY INDEX

14%

INTERNET SOURCES

4%

PUBLICATIONS

0%

STUDENT PAPERS

---

## PRIMARY SOURCES

---

1	<a href="http://www.ncbi.nlm.nih.gov">www.ncbi.nlm.nih.gov</a> Internet Source	7%
2	<a href="http://www.oculist.net">www.oculist.net</a> Internet Source	4%
3	Brandon J. Baartman, Andrew Bauer, Ferdinand Hui, Lisa Lystad, Arun D. Singh. "Dural Arteriovenous Fistula Presenting with Purely Contralateral Ophthalmic Manifestations", Ocular Oncology and Pathology, 2017 Publication	3%
4	Marshalyn G. McKoy, Ya Fatou Njie-Mbye, Catherine A. Opere. "Ocular autonomic physiology and pharmacology", Elsevier BV, 2022 Publication	1%
5	<a href="http://archive.org">archive.org</a> Internet Source	1%

---

Exclude quotes Off

Exclude matches Off

Exclude bibliography On