


BUKTI KORESPONDENSI JURNAL NASIONAL

Judul Artikel : *Fixed Partial Denture Treatment In The Case Of Extruded Antagonistic Teeth: Case Report*  
 Koresponden : Dika Agung Bakhtiar  
 Penulis : Dika Agung Bakhtiar, Qonitah Nur Aslamiyah  
 Jurnal : Indonesian Journal of Dentistry


No	Keterangan	Tanggal
1	Submit Artikel	16 November 2024
2	Hasil Review	30 Januari 2025
3	Submit Revisi	10 Februari 2025
4	Artikel Accepted	11 Februari 2025
5	Publikasi Artikel	20 Februari 2025

**Publisher**



Faculty of Dentistry  
Universitas Muhammadiyah Semarang

**Indexing Sites**



Home > User > Author > Submissions > #16310 > Summary

### #16310 Summary

SUMMARY REVIEW EDITING

**Submission**

Authors: Dika Agung Bakhtiar, Qonitah Nur Aslamiyah  
 Title: FIXED PARTIAL DENTURE TREATMENT IN THE CASE OF EXTRUDED ANTAGONISTIC TEETH CASE REPORT  
 Original File: 16310-49338-1-SM.DOCX - 2024-11-16  
 Supps. files: None  
 Submitter: drg Dika Agung Bakhtiar  
 Date submitted: November 16, 2024 - 10:11 AM  
 Section: Articles  
 Editor: Nur Sholehah  
 Abstract Views: 0

**Status**

Status: Published - Vol 5, No 1 (2025) Februari 2025  
 Initiated: 2025-02-20  
 Last modified: 2025-02-21

**Submission Metadata**

Authors

Focus and Scope

Peer Review Process

Open Access Policy

Author Guidelines

Copyright Notice

Author Fees

Editorial Team


drg Ani Heggwati, Sp.PM  
Editor in Chief  
Universitas Muhammadiyah Semarang

drg Hagus Falaufa, MSc  
Co-Editor in Chief  
Universitas Muhammadiyah Semarang

drg Nur Khamlatyng Sholehah, MEd  
Associate Editor  
Universitas Muhammadiyah Semarang


drg Vika Dian Rahmandasari  
Associate Editor  
Universitas Muhammadiyah Semarang

**Publisher**




Faculty of Dentistry  
Universitas Muhammadiyah Semarang

**Indexing Sites**



**Recommended Tools**



Home > User > Author > Submissions > #16310 > Review

### #16310 Review

SUMMARY REVIEW EDITING

**Submission**

Authors: Dika Agung Bakhtiar, Qonitah Nur Aslamiyah  
 Title: FIXED PARTIAL DENTURE TREATMENT IN THE CASE OF EXTRUDED ANTAGONISTIC TEETH CASE REPORT  
 Section: Articles  
 Editor: Nur Sholehah

**Peer Review**

**Round 1**

Review Version: 16310-49338-1-RV.DOCX - 2024-11-16  
 Initiated: 2025-01-18  
 Last modified: 2025-01-31  
 Uploaded file: None

**Editor Decision**

Decision: Accept Submission - 2025-02-11  
 Notify Editor: Editor/Author Email Record - 2025-02-11  
 Editor Version: 16310-51753-1-ED.DOCX - 2025-02-01  
 Author Version: 16310-51756-1-ED.DOCX - 2025-02-10 DELETE  
 16310-50996-1-ED.DOCX - 2025-02-10 DELETE

Upload Author Version:  No file chosen

Peer Review Process

Open Access Policy

Author Guidelines

Copyright Notice

Author Fees

Editorial Team

drg Ani Heggwati, Sp.PM  
Editor in Chief  
Universitas Muhammadiyah Semarang

drg Hagus Falaufa, MSc  
Co-Editor in Chief  
Universitas Muhammadiyah Semarang

drg Nur Khamlatyng Sholehah, MEd  
Associate Editor  
Universitas Muhammadiyah Semarang

drg Vika Dian Rahmandasari  
Associate Editor  
Universitas Muhammadiyah Semarang

drg Henrika Dyan Ayu Munko Sari, MEd, Sp.KGA  
Associate Editor  
Universitas Muhammadiyah Semarang

drg Nira Ardiya, MSc

[jjd] Editor Decision External Inbox x



**Nur Khamilatussy Sholekhah** <jurnal@unimus.ac.id>  
to me, Gonitah

Sat, Feb 1, 8:31AM ☆ ↶ ⋮

drg Dika Agung Bakhtiar:

We have reached a decision regarding your submission to Indonesian Journal of Dentistry, "FIXED PARTIAL DENTURE TREATMENT IN THE CASE OF EXTRUDED ANTAGONISTIC TEETH: CASE REPORT".

Our decision is to: Revision Required

Nur Khamilatussy Sholekhah  
Faculty of Dentistry, University Muhammadiyah Semarang  
Phone 081227384765  
Fax 02476740241  
[drg.lusy@unimus.ac.id](mailto:drg.lusy@unimus.ac.id)

-----\*&

Reviewer B:  
Untuk Author, mohon disrevisi sesuai komentar tang tercantum

Dental Journal  
<https://jurnal.unimus.ac.id/index.php/DJ>

[jjd] Editor Decision External



**Nur Khamilatussy Sholekhah**  
to me, Gonitah

Tue, Feb 11, 1:52 PM (10 days ago) ☆ ↶ ⋮

drg Dika Agung Bakhtiar:

We have reached a decision regarding your submission to Indonesian Journal of Dentistry, "FIXED PARTIAL DENTURE TREATMENT IN THE CASE OF EXTRUDED ANTAGONISTIC TEETH: CASE REPORT".

Our decision is to: Accepted Submission

Nur Khamilatussy Sholekhah  
Faculty of Dentistry, University Muhammadiyah Semarang  
Phone 081227384765  
Fax 02476740241  
[drg.lusy@unimus.ac.id](mailto:drg.lusy@unimus.ac.id)

-----\*&

Indonesian Journal of Dentistry  
<https://jurnal.unimus.ac.id/index.php/DJ>



**Indonesian Journal Dentistry (IJD)**

Website: <https://jurnal.unimus.ac.id/index.php/IJD/index>

Email: [dentaljournal@unimus.ac.id](mailto:dentaljournal@unimus.ac.id)

Handphone: 083805938393 / 081227384765

---

## **LETTER OF ACCEPTANCE**

February, 11<sup>th</sup>, 2025

Dear Author,

On behalf of Indonesian Journal of Dentistry Editorial, we are pleased to inform you that your paper entitled:

**“FIXED PARTIAL DENTURE TREATMENT IN THE CASE OF EXTRUDED  
ANTAGONISTIC TEETH: CASE REPORT”**

written by: Dika Agung Bakhtiar

has been accepted and will be published in Indonesian Journal of Dentistry Volume 5, Number 1, February 2025

Regards,

drg. Ani Megawati, Sp.PM.

Chief Editor

**Indonesian Journal of Dentistry** has been indexed in:



## FIXED PARTIAL DENTURE TREATMENT IN THE CASE OF EXTRUDED ANTAGONISTIC TEETH: CASE REPORT

### Keywords:

Extrusion, Fixed partial denture, Hygienic pontic

### ABSTRACT

**Background:** Permanent first molar teeth are the key to determining occlusion in dental development. One of the consequences of lower first molar tooth loss is upper first molar tooth extrusion. Tooth loss leads to structural changes in the dental arch, so replacing the missing teeth as soon as possible is important. This can be achieved with the help of a fixed partial denture.

**Case:** A 21-year-old female patient came to the Prosthodontic Department of UNIMUS RSGMP in May 2024, complaining of discomfort and chewing food difficulty, the patient also felt that her upper molars began to look elongated. The treatment results showed no complaints, good retention, stabilization and occlusion of the fixed partial denture.

**Conclusion:** Fixed partial denture treatment with hygienic pontic in cases of extruded antagonistic teeth shows a good level of treatment success characterized by the absence of complaints of either a sense of blocking when chewing food or speaking, no signs of inflammation or trauma as well as good retention, stabilization, and occlusion of the fixed partial denture.

### INTRODUCTION

Permanent first molar teeth are the key to determining occlusion in dental development, play a major role in bearing masticatory loads, choosing the vertical dimensions of the face, and play a small role in aesthetic factors.<sup>1</sup> Permanent first molar teeth are the most vulnerable teeth to dental caries. This is due to morphological and functional characteristics, eruption time, tooth position, and environmental influences.<sup>2</sup> As we age, untreated caries will worsen and lead to tooth loss. One of the effects of lower first molar tooth loss is upper first molar tooth extrusion. Extrusion is the movement of the tooth out of the alveolus, where the root follows the crown.<sup>3</sup> This occurs due to the absence of occlusion contact that can withstand chewing, resulting in the tooth losing its regular normal stimulation. Research in Indonesia conducted by Mangkat et al. showed that the M-T (Missing-teeth) index in the age group under 30 years was 3.4%.<sup>4</sup>

Tooth loss disrupts the structure of the dental arch, so it is important to replace the missing teeth as soon as possible. This can be achieved with the help of a fixed partial denture (FPD). FPD is a denture that replaces one or more missing teeth permanently attached to the remaining tooth structure so the patient cannot remove it.<sup>5</sup> It is called a bridge because it bridges the gap caused by missing teeth. Indications for the use of FPD, namely replacing one or more missing teeth, natural teeth still limit the

**Commented [MOU1]:** • Explain in more detail the specific reasons for using a hygienic pontic in this case, whether it is due to vertical space limitations, aesthetic concerns, or functional needs.  
• Add several citations or references that support the use of FPD with a pontic design in cases of tooth extrusion to strengthen the scientific basis of this case report.

toothless area on both sides, the supporting teeth must be healthy, the periodontal tissue is adequate, and the patient is aged 20-55.<sup>6</sup>

The components of a fixed partial denture consist of abutments, retainers, connectors and pontics (dummy). In these restorations, the pontic must fulfil the complex role of replacing the function of missing teeth, achieving aesthetic appearance, allowing adequate oral hygiene and preventing tissue irritation. In addition, the pontic must also meet structural requirements to ensure the mechanical stability of the restoration.<sup>7</sup> The pontic design should provide a functional and aesthetic replacement for the missing tooth. The location of the missing tooth, either anteriorly or posteriorly, is a very important consideration. In the anterior region, aesthetic factors are a concern, the pontic should be customised to make it appear as if it is emerging from the gingiva. Conversely, the contour can be modified in the posterior region for a less aesthetic but acceptable oral hygiene design.<sup>8</sup>

Hygienic pontics have a gap between the pontic and the ridge of about 2-3 mm, excellent for posterior teeth and in conditions of inadequate oral hygiene.<sup>9</sup> Hygienic pontics are a type of pontic that does not contact the ridge mucosa; this can facilitate cleaning. The hygienic pontic design facilitates plaque control because it allows the cleaning tool to clean the area under the pontic. Inflammation of the mucosa and gingiva can be effectively prevented with this design. The disadvantages of this type of pontic are that it does not look natural so aesthetically, it is lacking, and there are contraindications in the minimal vertical dimension.<sup>10</sup>

The purpose of this case report is to convey the success of fixed partial denture treatment with hygienic pontics in the case of extruded antagonistic teeth where the teeth can function properly and restore masticatory function.

## **CASE**

A 21-year-old female patient came to the Prosthodontic Department of UNIMUS RSGMP in May 2024, complaining of discomfort and difficulty when chewing food, the patient also felt that her upper molars began to look elongated. The anamnesis results showed that his lower right molar had been extracted about two years ago. The patient was in good health. The patient denied having any systemic disease. The patient has no history of drug, food or weather allergies. The patient wanted a denture made.

The general examination of the patient was good. The extraoral examination revealed no abnormalities, and the intraoral examination revealed that tooth 46 was missing (Figure 1), with tooth 16 extruded. Panoramic radiographic examination showed extrusion of tooth 16, normal periodontal ligament tissue and adequate bone in teeth 45 and 47 (Figure 2). Based on the results of the history, clinical examination and supporting examination of the patient, the diagnosis of this case is an

edentulous ridge of tooth 46. The treatment plan for tooth 46 is to make a Porcelain Fused-to-metal (PFM) fixed partial denture with hygienic pontics.

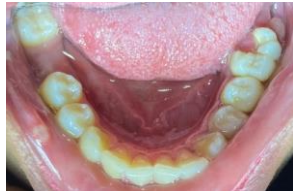

Figure 1. The edentulous region of tooth 46.

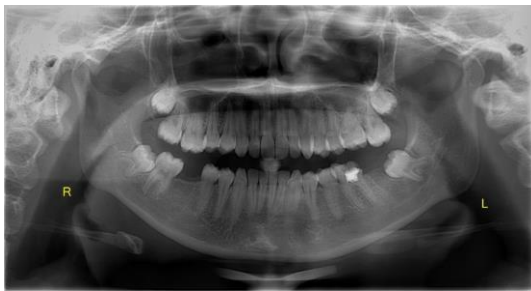

Figure 2. Panoramic Radiograph.

#### CASE MANAGEMENT

At the first visit, subjective, objective examination, supporting examination and printing of the study model were carried out. Then the FPD design was made, in this case using Porcelain Fused to Metal (PFM) material with hygienic pontic, full veneer retainer, rigid connector and teeth 45 and 47 as abutment. The stages of making FPD (Figure 3) begin with the preparation of abutment teeth 45 and 47 on the study model using a high-speed diamond bur with the provisions of occlusal preparation 1.5-2 mm, buccal 0.5-1 mm, lingual 0.5-1 mm and proximal 1-1.5 mm. The results of the abutment tooth preparation are made with dental anatomy with diagnostic wax-up, which will be used for creating a provisory bridge (temporary crown).

On the second visit, preparation was carried out on the abutment teeth. First, infiltration anaesthesia was performed on the mucobuccal fold and lingual teeth to be prepared, namely teeth 45 and 47, to avoid pain during preparation. Then, a gingival cord is placed to retract the gingiva around the abutment tooth to get the edge of the preparation at the gingiva level (equigingiva). Preparation was carried out starting from tooth 45 and then proceeding to tooth 47 under the provisions of abutment tooth preparation on the study model simulation. After completion of the preparation, functional impression was performed with a one-step technique using double impression putty and elastomer material. The results of this dental working model mould were used to make metal copings with

hygienic pontics in the Laboratory. The prepared teeth were fitted with a protective bridge and temporary cementation using zinc oxide eugenol (ZOE).

Third visit, open the provisory bridge and clean and dry the abutment area. Try in metal coping on the patient. Make sure there is no discomfort or open bite on the opposite side, when trying in the metal coping, the teeth should not be in contact, the aim is to make a distance between the PFM and the antagonistic tooth contacts. Proximal contact between the FPD and the adjacent teeth and the edge of the fixed partial denture should not press on the gingiva. Then the porcelain colour is selected according to the colour of the natural teeth with the Vita-shade guide. The metal coping was sent back to the Laboratory for PFM manufacturing. The provisory bridge was re-fitted using temporary cementation.

On the fourth visit, the Provisory bridge was opened. Try in the FPD, what we must considered is the retention, stabilization and occlusion. If there were no complaints and the denture fit well, fixed the FPD with temporary cementation using Zinc Oxide Eugenol (ZOE). Evaluate 1 week after temporary FPD cementation to see if the patient feels any complaints. The subjective examination is carried out by asking whether there are complaints after the FPD is installed and worn, how it feels when used for eating, and whether there is a sense of blocking and discomfort. For the objective examination we looks at the state of the oral tissue and soft tissue in the area around the FPD, whether there is inflammation, and whether there is redness or other signs of trauma. The FPD's retention, stabilization, and occlusion are also checked.

The FPD was opened and cleared of any remaining temporary cementation on the fifth visit. Then we dry the abutment teeth 45 and 47 and permanently cement the FPD using Type I Glass Ionomer Cement (GIC). After the cementation, patient instructed to bite the cotton roll for a few minutes to apply maximum pressure, and the remaining cement around the FPD is cleaned. Instruct the patient to maintain oral hygiene and ask not to eat or chewing hard food first. The patient is instructed to follow up 24 hours and 1 week post insertion. Post-insertion evaluation of FPD for 24 hours and 1 week was carried out, the patient did not feel any complaints during the FPD was installed and worn, the patient could chew food easily, and there was no blocking and discomfort. On objective examination, the condition of the oral and soft tissues in the area around the FPD there is no sign of inflammation, redness or other signs of trauma. Retention, stabilization, and occlusion of the FPD are good.

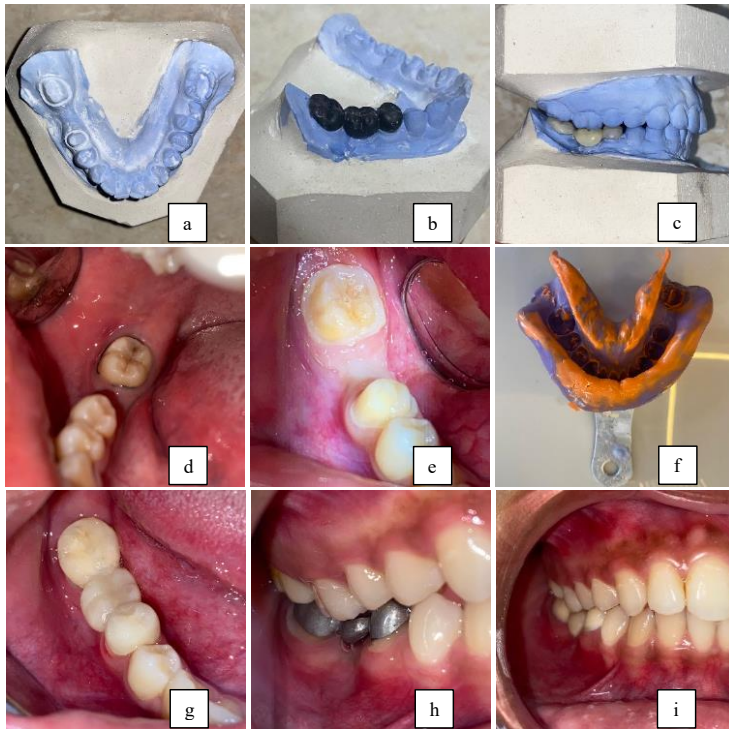


Figure 3. (a) Study model preparation, (b) Dental anatomy using diagnostic wax-up, (c) Provisionary bridge, (d) Gingival cord was placed, (e) Preparation of abutment teeth 45 and 47, (f) Functional impression, (g) Provisionary bridge temporary cementation, (h) Try in metal coping, (i) FPD insertion.

## DISCUSSION

The main purpose of dental treatment with a fixed partial denture is to maintain the health of the remaining teeth and the entire masticatory system so that it can function properly.<sup>11</sup> Also, making a fixed partial denture aims to restore masticatory function and psychological benefits, prevent further damage, improve the appearance and speech function, maintain dental health, and prevent disorders in the temporomandibular joint.<sup>12</sup> Loss of lower molars is common and disrupts a person's masticatory function. Loss of posterior teeth will result in loss of occlusion followed by extrusion of antagonistic teeth. Extrusion causes the crown to look longer.<sup>13</sup>

Extrusion of antagonistic teeth in manufacturing a fixed partial denture is certainly a challenge. Replacement teeth or pontics determine occlusion in a fixed partial denture. Pontics that serve as replacements for missing teeth must be considered for their design in terms of mechanical, biological and aesthetic demands. The shape and size of the selected pontic must be regarded under the position of the edentulous space, the amount of bone resorption, and the position of the antagonistic teeth to

**Commented [MOU2]: Clarify the Long-Term Maintenance of Fixed Partial Dentures (FPD):** While the discussion emphasizes the importance of patient cooperation and evaluation during treatment visits, it would be beneficial to elaborate on the long-term maintenance of the fixed partial denture, especially for patients who have a hygienic pontic design.

**Include Consideration of Alternative Pontic Designs:** While the discussion justifies the use of hygienic pontics for this case, it might be valuable to include a brief mention of alternative pontic designs that could also be considered in cases with similar conditions, such as ovate pontics or ridge-lap pontics, which may offer better aesthetic outcomes.



achieve good occlusion. In addition, selecting pontics should allow for adequate oral hygiene and prevent tissue irritation.<sup>7</sup>

Hygienic pontics were chosen based on the patient's clinical examination of missing tooth 46. This design mainly replaces mandibular first molars, restores occlusal function, or stabilize neighbouring and antagonistic teeth. This pontic design is recommended for posterior teeth as it has good self-cleansing access for oral hygiene supported by the pontic distance to the periodontal tissues of 2-3 mm. This design is indicated for areas or zones that do not require high aesthetic value but poor oral hygiene. The disadvantage of this design is the lack of aesthetic value.<sup>8</sup>

The selection of tooth 45 and tooth 47 as abutment teeth were under Ante's law, which states, "The root surface area of the abutment tooth should be equal to or greater than that of the tooth to be replaced". Full Veneer Retainer was chosen because of its advantage of providing the best retention and resistance and splinting effect, while the disadvantage is that more tooth tissue is reduced. Connectors prevent distortion or fracture during denture function. Rigid connectors are chosen because they are strong and can withstand masticatory pressure. Porcelain Fused to Metal restorations combines metal's strength with porcelain's aesthetics to achieve good aesthetics. The metal framework of PFM is strong enough to withstand chewing loads and is stable and durable.<sup>14</sup>

Poor fixed partial denture manufacturing stages can lead to the failure of Porcelain Fused to Metal restorations. Some things that affect this include the thickness of the abutment tooth preparation, which is too little or too much tissue reduction. If the teeth reduction is too little, it can cause occlusion trauma due to the FPD that blocks or requires selective grinding of the antagonist teeth, where the risk is the onset of pain due to the reduction of antagonist tooth enamel tissue. If the reduction in abutment tooth preparation is too much, it results in soreness due to thin dentin tissue. Another thing that affects FPD failure is the accuracy of the functional impression results, if the impression anatomy is not appropriate, the FPD would not be retentive and stable. In addition, the thickness of the metal coping and porcelain must be considered, if the metal coping is too thin (less than 0.4 mm), the porcelain will experience shrinkage, distorting the metal coping. Insufficient thickness of the metal coping in the occlusal region will result in metal deformation under mastication stress. Therefore, the metal coping in the occlusal region should be sufficiently thick and wide.<sup>15</sup>

In this case, the success of fixed partial denture treatment was based on patient motivation, where the patient realised the health of his teeth and oral cavity before a more severe case of antagonistic tooth extrusion and other problems occurred. In addition, the patient's ability to cooperate in several treatment visit made this fixed partial denture treatment optimal. Evaluation and control of each fixed partial denture treatment visit are carried out so that the main goal of treatment is achieved,

where the goal is to maintain the health of the remaining teeth and the entire masticatory system so that it can function properly.

## CONCLUSION

Fixed partial denture treatment with hygienic pontic in cases of extruded antagonistic teeth shows a good level of treatment success, characterized by the absence of complaints of a sense of blocking when chewing food or talking, no signs of inflammation or trauma, good retention, stabilization and occlusion of the fixed partial denture.

## ACKNOWLEDGEMENT

Thank you for all of the parties who have supported in this research.




## REFERENCES

1. Aras A, Dogan MS. Caries Prevalence and Severity in Immature Permanent First Molar Teeth in Sanliurfa City, Turkey. *J Dent Indones* 2020; 27:13. DOI: 10.14693/jdi.v27i1.1114
2. Salma, A. F. F., Boenjamin, F., & Jeddy, J. (2021). Perbedaan Keparahan Karies Gigi Molar Pertama Pada Anak Usia 6-9 Tahun Dengan 10-12 Tahun: Kajian Pada Radiograf Panoramik Di Rsgm-P Fkg Universitas Trisakti Periode 2017-2019 (Laporan Penelitian). *Jurnal Kedokteran Gigi Terpadu*, 3(1).
3. Amin, M. N., & Permatasari, N. (2017). Aspek biologis pergerakan gigi secara ortodonsi. *Stomatognatic-Jurnal Kedokteran Gigi*, 13(1), 22-27.
4. Mangkat Y, Wowor VNS, Mayulu N. Pola kehilangan gigi pada masyarakat Desa Roong Kecamatan Tondano Barat Minahasa Induk. *e-Gigi J Ilmiah Ked Gi*. 2015;3(2):508-14. DOI: [10.35790/eg.3.2.2015.10015](https://doi.org/10.35790/eg.3.2.2015.10015)
5. Prawesthi, E., & Handayani, S. (2023). Pembuatan Mahkota Tiruan All Zirconia Multilayered CAD/CAM Pada Pasien Dengan Dukungan Gigi Implan Tipe Endosseus (Laporan Kasus). *Jurnal Ilmiah dan Teknologi Kedokteran Gigi*, 19(2), 86-92.
6. Redi Y. (2019). Prosedur Pembuatan Gigi Tiruan Jacket Crown All Acrylic Pada Gigi 11 Dan 21 Dengan Gigi Tiruan Sebagian Lepas Saddle Acrylic Pada Gigi 25. *Repos Poltekkes Tanjungkarang*;4-22.
7. Tiku, Y. G. S., & Jubhari, E. H. (2019). Selection of pontic design. *Makassar Dental Journal*, 8(3).
8. Rosenstiel, S. F., Martin, F. L., & Junhei, F. 2016. *Contemporary Fixed Prosthodontics*. Fifth Edition. Elsevier: Missouri.
9. Bukhari, M., Aldossari, A., & Alyami, I. (2022). Pontic design and its effects on the health of the gingiva. *International Journal Of Community Medicine And Public Health*, 9, 4725. DOI: [10.18203/2394-6040.ijcmph20223238](https://doi.org/10.18203/2394-6040.ijcmph20223238)
10. Rosenstiel S. F., Martin, F. L., & Waiter R. D., 2023. *Contemporary Fixed Prosthodontics*, Sixth Edition. Elsevier, Philadelphia.
11. Kusdarjanti, E., Setyowati, O., & Zseni, F. (2019). Making Single Complete Dentures for the Material with Tuber Maxilla Case Large. *Journal of Vocational Health Studies*, 3(1), 37-39. DOI: 10.20473/jvhs.V3.I1.2019.37-39
12. Sofya, P. A. (2022). Tingkat Pengetahuan Mahasiswa Program Studi Pendidikan Dokter Terhadap Gigi Tiruan Jembatan. *Jurnal Ilmiah Teknologi Kedokteran Gigi*, 18(1).
13. Panjaitan, E. F., Paramakirana, H., Santosa, P., & Rinastiti, M. (2022). Perawatan Ekstrusi Dan Luksasi Gigi Molar Satu Mandibula Dengan Restorasi Endocrown Fiber Reinforced Composite. *Jurnal Kedokteran Gigi Universitas Padjajaran*, (3):28-36. DOI: [10.24198/jkg.v33i3.33250](https://doi.org/10.24198/jkg.v33i3.33250)
14. Arafah, C. N. H., Shofiyah, N., Wasyim, A. H. P., Maharani, A. K., Kintami, T. G., Hardita, A., ... & Ramadhani, V. (2024). Perawatan Gigi Tiruan Jembatan dengan Sanitary Pontic. *STOMATOGNATIC-Jurnal Kedokteran Gigi*, 21(2), 171-175.
15. Sinamo, S., Caesarina, D., Maghfira, V., & Halim, S. (2022). Laporan Kasus: Gigi Tiruan Cekat. *Prima Journal of Oral and Dental Sciences*, 5(1), 63-68. DOI: [10.34012/primajods.v5i1.2879](https://doi.org/10.34012/primajods.v5i1.2879)



# S1 Kedokteran Gigi

## drg Dika

-  drg Aliemuddin
-  Cek Similaritas 1 drg Aliemuddin
-  Universitas Muhammadiyah Semarang

---

### Document Details

Submission ID

trn:oid::1:3161708104

Submission Date

Feb 21, 2025, 1:37 PM GMT+7

Download Date

Feb 21, 2025, 1:38 PM GMT+7

File Name

16310-52213-1-PB.pdf

File Size

417.4 KB

9 Pages

3,636 Words

19,137 Characters





# 21% Overall Similarity

The combined total of all matches, including overlapping sources, for each database.




## Filtered from the Report

- ▶ Bibliography
- ▶ Quoted Text

## Match Groups

-  **35 Not Cited or Quoted 20%**  
Matches with neither in-text citation nor quotation marks
-  **1 Missing Quotations 1%**  
Matches that are still very similar to source material
-  **0 Missing Citation 0%**  
Matches that have quotation marks, but no in-text citation
-  **0 Cited and Quoted 0%**  
Matches with in-text citation present, but no quotation marks

## Top Sources

- 19%  Internet sources
- 10%  Publications
- 12%  Submitted works (Student Papers)

## Integrity Flags

### 0 Integrity Flags for Review

No suspicious text manipulations found.

Our system's algorithms look deeply at a document for any inconsistencies that would set it apart from a normal submission. If we notice something strange, we flag it for you to review.

A Flag is not necessarily an indicator of a problem. However, we'd recommend you focus your attention there for further review.

### Match Groups

- 35** Not Cited or Quoted 20%  
Matches with neither in-text citation nor quotation marks
- 1** Missing Quotations 1%  
Matches that are still very similar to source material
- 0** Missing Citation 0%  
Matches that have quotation marks, but no in-text citation
- 0** Cited and Quoted 0%  
Matches with in-text citation present, but no quotation marks

### Top Sources

- 19% Internet sources
- 10% Publications
- 12% Submitted works (Student Papers)

### Top Sources

The sources with the highest number of matches within the submission. Overlapping sources will not be displayed.

<b>1</b>	Internet	jurnal.unimus.ac.id	5%
<b>2</b>	Internet	pmc.ncbi.nlm.nih.gov	5%
<b>3</b>	Internet	jdas.in	4%
<b>4</b>	Student papers	October University for Modern Sciences and Arts (MSA)	1%
<b>5</b>	Student papers	South Nottingham College, Nottinghamshire	1%
<b>6</b>	Internet	jurnal.unprimdn.ac.id	<1%
<b>7</b>	Student papers	Yeditepe University	<1%
<b>8</b>	Internet	es.scribd.com	<1%
<b>9</b>	Student papers	Fiji National University	<1%
<b>10</b>	Publication	Matthew J Gahan, Peter J Nixon, Stephen Robinson, Martin F W-Y Chan. "The ovat...	<1%

11	Internet	ebin.pub	<1%
12	Internet	jurnal.unpad.ac.id	<1%
13	Publication	Kim, T.H.. "Simulated tissue using a unique pontic design: A clinical report", The J...	<1%
14	Publication	V. T. Beena, R. Sivakumar, R. Heera, R. Rajeev, Kanaram Choudhary, Swagatika Pa...	<1%
15	Internet	jurnal.pdgi.or.id	<1%
16	Internet	www.jidmr.com	<1%
17	Internet	bmcoralhealth.biomedcentral.com	<1%

## FIXED PARTIAL DENTURE TREATMENT IN THE CASE OF EXTRUDED ANTAGONISTIC TEETH: CASE REPORT

Dika Agung Bakhtiar<sup>1</sup>, Qonitah Nur Aslamiyah<sup>2</sup>

1. Department of Prosthodontic, Faculty of Dentistry, Universitas Muhammadiyah Semarang
2. Faculty of Dentistry, Universitas Muhammadiyah Semarang

Correspondence: [drg.dika@unimus.ac.id](mailto:drg.dika@unimus.ac.id)

Received November 16<sup>th</sup>, 2024; 1<sup>st</sup> Revision January 30<sup>th</sup>, 2025; Accepted February 11<sup>th</sup>, 2025; Published online February 20<sup>th</sup>, 2025.

### Keywords:

*Extrusion, Fixed partial denture, Hygienic pontic*

Indonesian Journal of Dentistry  
Volume 5 No 1 Issue 1 Year 2025 Pages 1-9  
URL <https://jurnal.unimus.ac.id/index.php/IJD>  
DOI <https://doi.org/10.26714/ijjd.v5i1.16310>

### ABSTRACT

**Background:** Permanent first molar teeth are the key to determining occlusion in dental development. One of the consequences of lower first molar tooth loss is upper first molar tooth extrusion. Tooth loss leads to structural changes in the dental arch, so replacing the missing teeth as soon as possible is important. This can be achieved with the help of a fixed partial denture.

**Case:** A 21-year-old female patient came to the Prosthodontic Department of UNIMUS RSGMP in May 2024, complaining of discomfort and chewing food difficulty, the patient also felt that her upper molars began to look elongated. The treatment results showed no complaints, good retention, stabilization and occlusion of the fixed partial denture.

**Conclusion:** Fixed partial denture treatment with hygienic pontic in cases of extruded antagonistic teeth shows a good level of treatment success characterized by the absence of complaints of either a sense of blocking when chewing food or speaking, no signs of inflammation or trauma as well as good retention, stabilization, and occlusion of the fixed partial denture.

## INTRODUCTION

Permanent first molar teeth are the key to determining occlusion in dental development, play a major role in bearing masticatory loads, choosing the vertical dimensions of the face, and play a small role in aesthetic factors.<sup>1</sup> Permanent first molar teeth are the most vulnerable teeth to dental caries. This is due to morphological and functional characteristics, eruption time, tooth position, and environmental influences.<sup>2</sup> As we age, untreated caries will worsen and lead to tooth loss. One of the effects of lower first molar tooth loss is upper first molar tooth extrusion. Extrusion is the movement of the tooth out of the alveolus, where the root follows the crown.<sup>3</sup> This occurs due to the absence of occlusion contact that can withstand chewing, resulting in the tooth losing its regular normal stimulation. Research in Indonesia conducted by Mangkat et al. showed that the M-T (Missing-teeth) index in the age group under 30 years was 3.4%.<sup>4</sup>



1

4 Tooth loss disrupts the structure of the dental arch, so it is important to replace the missing teeth as soon as possible. This can be achieved with the help of a fixed partial denture (FPD). FPD is a denture that replaces one or more missing teeth permanently attached to the remaining tooth structure so the patient cannot remove it.<sup>5</sup> It is called a bridge because it bridges the gap caused by missing teeth. Indications for the use of FPD, namely replacing one or more missing teeth, natural teeth still limit the toothless area on both sides, the supporting teeth must be healthy, the periodontal tissue is adequate, and the patient is aged 20-55.<sup>6</sup>

3

5

7

The components of a fixed partial denture consist of abutments, retainers, connectors and pontics (dummy). In these restorations, the pontic must fulfil the complex role of replacing the function of missing teeth, achieving aesthetic appearance, allowing adequate oral hygiene and preventing tissue irritation. In addition, the pontic must also meet structural requirements to ensure the mechanical stability of the restoration.<sup>7</sup> The pontic design should provide a functional and aesthetic replacement for the missing tooth. The location of the missing tooth, either anteriorly or posteriorly, is a very important consideration. In the anterior region, aesthetic factors are a concern, the pontic should be customised to make it appear as if it is emerging from the gingiva. Conversely, the contour can be modified in the posterior region for a less aesthetic but acceptable oral hygiene design.<sup>8</sup>

2

There are several pontic design that can be used in FPD, for the maxillary anterior segment, the ridge lap pontic was the most common (32%) followed by the modified ridge lap (28%). In the maxillary posterior segment, the ridge lap pontic was the most common (37%) followed by sanitary design (34%). For the mandibular anterior segment, the modified ridge lap (50%) was the common followed by ridge lap pontic (17%). In case of the mandibular posterior segment, the sanitary design (34%) was te most common followed by ridge lap pontic (30%).<sup>17</sup>

3

3

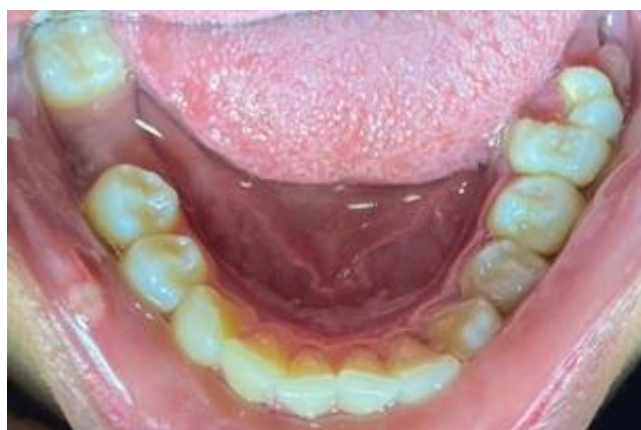Hygienic pontics have a gap between the pontic and the ridge of about 2-3 mm, excellent for posterior teeth and in conditions of inadequate oral hygiene .<sup>9</sup> Hygienic pontics are a type of pontic that does not contact the ridge mucosa; this can facilitate cleaning. The hygienic pontic design facilitates plaque control because it allows the cleaning tool to clean the area under the pontic. Inflammation of the mucosa and gingiva can be effectively prevented with this design. The disadvantages of this type of pontic are that it does not look natural so aesthetically, it is lacking, and there are contraindications in the minimal vertical dimension.<sup>10</sup> In addition of hygienic pontic there is modified ovate pontic design, that was developed to circumvent the problems encountered with the ovate pontic. The modification of the ovate pontic involves moving the height of contour at the tissue surface from the center of the base to a more labial position. The modified ovate pontic does not require as much faciolingual thickness to create emergence profile.<sup>16</sup>

The purpose of this case report is to convey the success of fixed partial denture treatment with hygienic pontics in the case of extruded antagonistic teeth where the teeth can function properly and restore masticatory function. Hygienic pontic used in lower posterior missing teeth in this case because this design described reproduce anatomic contours of certain portion of the buccal and lingual surfaces. This design was easy to keep clean which led to wider acceptance of this design among dentist and dental technicians.<sup>16</sup>

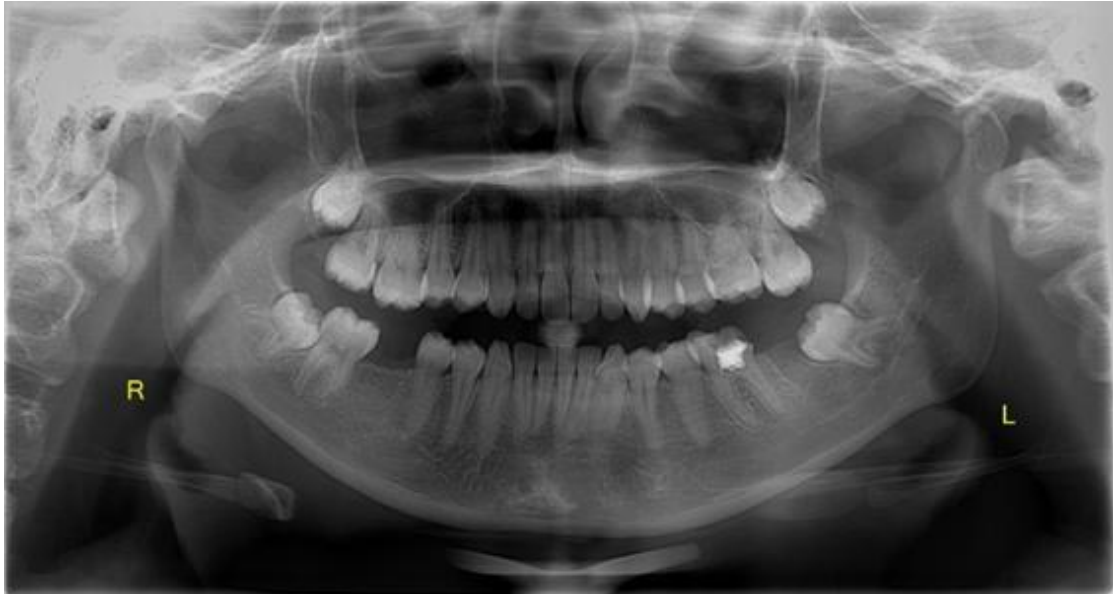## CASE

A 21-year-old female patient came to the Prosthodontic Department of UNIMUS RSGMP in May 2024, complaining of discomfort and difficulty when chewing food, the patient also felt that her upper molars began to look elongated. The anamnesis results showed that his lower right molar had been extracted about two years ago. The patient was in good health. The patient denied having any systemic disease. The patient has no history of drug, food or weather allergies. The patient wanted a denture made.

The general examination of the patient was good. The extraoral examination revealed no abnormalities, and the intraoral examination revealed that tooth 46 was missing (Figure 1), with tooth 16 extruded. Panoramic radiographic examination showed extrusion of tooth 16, normal periodontal ligament tissue and adequate bone in teeth 45 and 47 (Figure 2). Based on the results of the history, clinical examination and supporting examination of the patient, the diagnosis of this case is an edentulous ridge of tooth 46. The treatment plan for tooth 46 is to make a Porcelain Fused-to-metal (PFM) fixed partial denture with hygienic pontics.



**Figure 1.** The edentulous region of tooth 46



**Figure 2.** Panoramic Radiograph

## CASE MANAGEMENT

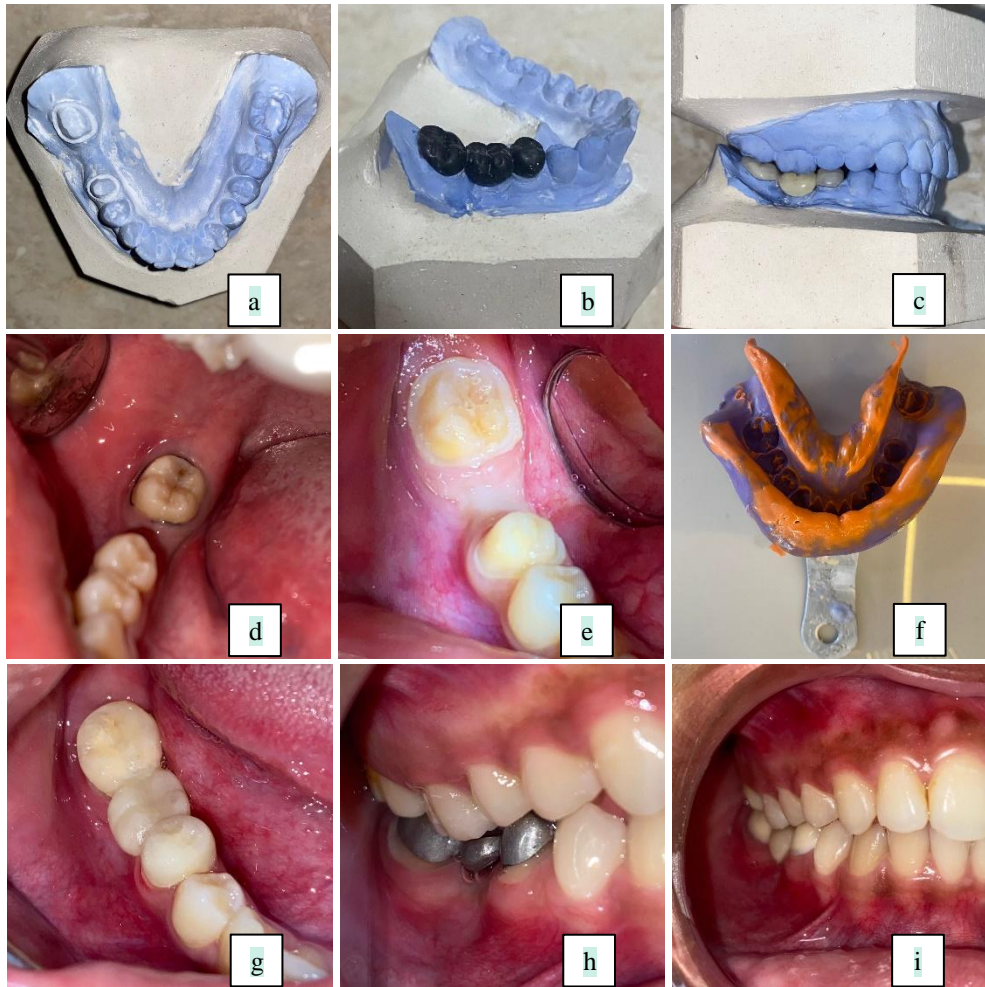At the first visit, subjective, objective examination, supporting examination and printing of the study model were carried out. Then the FPD design was made, in this case using Porcelain Fused to Metal (PFM) material with hygienic pontic, full veneer retainer, rigid connector and teeth 45 and 47 as abutment. The stages of making FPD (Figure 3) begin with the preparation of abutment teeth 45 and 47 on the study model using a high-speed diamond bur with the provisions of occlusal preparation 1.5-2 mm, buccal 0.5-1 mm, lingual 0.5-1 mm and proximal 1-1.5 mm. The results of the abutment tooth preparation are made with dental anatomy with diagnostic wax-up, which will be used for creating a provisory bridge (temporary crown).

On the second visit, preparation was carried out on the abutment teeth. First, infiltration anaesthesia was performed on the mucobuccal fold and lingual teeth to be prepared, namely teeth 45 and 47, to avoid pain during preparation. Then, a gingival cord is placed to retract the gingiva around the abutment tooth to get the edge of the preparation at the gingiva level (equigingiva). Preparation was carried out starting from tooth 45 and then proceeding to tooth 47 under the provisions of abutment tooth preparation on the study model simulation. After completion of the preparation, functional impression was performed with a one-step technique using double impression putty and elastomer material. The results of this dental working model mould were used to make metal copings with hygienic pontics in the Laboratory. The prepared teeth were fitted with a protective bridge and temporary cementation using zinc oxide eugenol (ZOE).

Third visit, open the provisory bridge and clean and dry the abutment area. Try in metal coping on the patient. Make sure there is no discomfort or open bite on the opposite side, when trying in the metal coping, the teeth should not be in contact, the aim is to make a distance between the PFM and the antagonistic tooth contacts. Proximal contact between the FPD and the adjacent teeth and the edge of the fixed partial denture should not press on the gingiva. Then the porcelain colour is selected according to the colour of the natural teeth with the Vita-shade guide. The metal coping was sent back to the Laboratory for PFM manufacturing. The provisory bridge was re-fitted using temporary cementation.

On the fourth visit, the Provisory bridge was opened. Try in the FPD, what we must considered is the retention, stabilization and occlusion. If there were no complaints and the denture fit well, fixed the FPD with temporary cementation using Zinc Oxide Eugenol (ZOE). Evaluate 1 week after temporary FPD cementation to see if the patient feels any complaints. The subjective examination is carried out by asking whether there are complaints after the FPD is installed and worn, how it feels when used for eating, and whether there is a sense of blocking and discomfort. For the objective examination we look at the state of the oral tissue and soft tissue in the area around the FPD, whether there is inflammation, and whether there is redness or other signs of trauma. The FPD's retention, stabilization, and occlusion are also checked.

The FPD was opened and cleared of any remaining temporary cementation on the fifth visit. Then we dry the abutment teeth 45 and 47 and permanently cement the FPD using Type I Glass Ionomer Cement (GIC). After the cementation, patient instructed to bite the cotton roll for a few minutes to apply maximum pressure, and the remaining cement around the FPD is cleaned. Instruct the patient to maintain oral hygiene and ask not to eat or chewing hard food first. The patient is instructed to follow up 24 hours and 1 week post insertion. Post-insertion evaluation of FPD for 24 hours and 1 week was carried out, the patient did not feel any complaints during the FPD was installed and worn, the patient could chew food easily, and there was no blocking and discomfort. On objective examination, the condition of the oral and soft tissues in the area around the FPD there is no sign of inflammation, redness or other signs of trauma. Retention, stabilization, and occlusion of the FPD are good.



**Figure 3.** (a) Study model preparation, (b) Dental anatomy using diagnostic wax-up, (c) Provisory bridge, (d) Gingival cord was placed, (e) Preparation of abutment teeth 45 and 47, (f) Functional impression, (g) Provisory bridge temporary cementation, (h) Try in metal coping, (i) FPD insertion

## DISCUSSION

The main purpose of dental treatment with a fixed partial denture is to maintain the health of the remaining teeth and the entire masticatory system so that it can function properly.<sup>11</sup> Also, making a fixed partial denture aims to restore masticatory function and psychological benefits, prevent further damage, improve the appearance and speech function, maintain dental health, and prevent disorders in the temporomandibular joint.<sup>12</sup> Loss of lower molars is common and disrupts a person's masticatory function. Loss of posterior teeth will result in loss of occlusion followed by extrusion of antagonistic teeth. Extrusion causes the crown to look longer.<sup>13</sup>

Extrusion of antagonistic teeth in manufacturing a fixed partial denture is certainly a challenge. Replacement teeth or pontics determine occlusion in a fixed partial denture. Pontics that serve as replacements for missing teeth must be considered for their design in terms of mechanical, biological and aesthetic demands. The shape and size of the selected pontic must be regarded under the position of the edentulous space, the amount of bone resorption, and the position of the antagonistic teeth to

1 achieve good occlusion. In addition, selecting pontics should allow for adequate oral hygiene and prevent tissue irritation.<sup>7</sup>

2 Different shapes of pontic are selected according to the position of the edentulous space, amount of bone resorption, and operator's and patient's preferences. It is recommended that the prosthodontist or the dental practitioner should advise the dental laboratory about the shape of the desired pontic for the fixed prosthesis. There is a variety of pontic designs (such as ridge lap, ovate and conical) for mandibular and maxillary arches.<sup>17</sup>

Hygienic pontics were chosen based on the patient's clinical examination of missing tooth 46. This design mainly replaces mandibular first molars, restores occlusal function, or stabilize neighbouring and antagonistic teeth. This pontic design is recommended for posterior teeth as it has good self-cleansing access for oral hygiene supported by the pontic distance to the periodontal tissues of 2-3 mm. This design is indicated for areas or zones that do not require high aesthetic value but poor oral hygiene. The disadvantage of this design is the lack of aesthetic value.<sup>8</sup>

17 The selection of tooth 45 and tooth 47 as abutment teeth were under Ante's law, which states, "The root surface area of the abutment tooth should be equal to or greater than that of the tooth to be replaced". Full Veneer Retainer was chosen because of its advantage of providing the best retention and resistance and splinting effect, while the disadvantage is that more tooth tissue is reduced. Connectors prevent distortion or fracture during denture function. Rigid connectors are chosen because they are strong and can withstand masticatory pressure. Porcelain Fused to Metal restorations combines metal's strength with porcelain's aesthetics to achieve good aesthetics. The metal framework of PFM is strong enough to withstand chewing loads and is stable and durable.<sup>14</sup>

Poor fixed partial denture manufacturing stages can lead to the failure of Porcelain Fused to Metal restorations. Some things that affect this include the thickness of the abutment tooth preparation, which is too little or too much tissue reduction. If the teeth reduction is too little, it can cause occlusion trauma due to the FPD that blocks or requires selective grinding of the antagonist teeth, where the risk is the onset of pain due to the reduction of antagonist tooth enamel tissue. If the reduction in abutment tooth preparation is too much, it results in soreness due to thin dentin tissue. Another thing that affects FPD failure is the accuracy of the functional impression results, if the impression anatomy is not appropriate, the FPD would not be retentive and stable. In addition, the thickness of the metal coping and porcelain must be considered, if the metal coping is too thin (less than 0.4 mm), the porcelain will experience shrinkage, distorting the metal coping. Insufficient thickness of the metal coping in the occlusal region will result in metal deformation under mastication stress. Therefore, the metal coping in the occlusal region should be sufficiently thick and wide.<sup>15</sup>

In this case, the success of fixed partial denture treatment was based on patient motivation, where the patient realised the health of his teeth and oral cavity before a more severe case of antagonistic tooth extrusion and other problems occurred. In addition, the patient's ability to cooperate in several treatment visit made this fixed partial denture treatment optimal. Evaluation and control of each fixed partial denture treatment visit are carried out so that the main goal of treatment is achieved, where the goal is to maintain the health of the remaining teeth and the entire masticatory system so that it can function properly. Regular dental check-ups are instrumental in the continued success of FPD. Used of hygienic pontic must recognize the heightened importance of meticulous oral care. They should follow dental professionals' guidance on proper brushing and flossing techniques, focusing not only on natural teeth but also on the areas around beneath the prostheses. Particular attention should be given to cleaning the margins where the FPD meets the natural teeth or abutments. The use of fluoride toothpaste is recommended to strengthen the natural tooth structure and protect against dental caries. Patients may also be advised to incorporate interdental brushes, dental floss, or water flossers into their daily routine to effectively clean interproximal spaces and remove plaque accumulation.<sup>18</sup>

## CONCLUSION

Fixed partial denture treatment with hygienic pontic in cases of extruded antagonistic teeth shows a good level of treatment success, characterized by the absence of complaints of a sense of blocking when chewing food or talking, no signs of inflammation or trauma, good retention, stabilization and occlusion of the fixed partial denture.

## ACKNOWLEDGMENT

Thank you to all the parties who have supported this research.

## REFERENCES

1. Aras A, Dogan MS. Caries Prevalence and Severity in Immature Permanent First Molar Teeth in Sanliurfa City, Turkey. *J Dent Indones* 2020; 27:13. DOI: 10.14693/jdi.v27i1.1114
2. Salma, A. F. F., Boenjamin, F., & Jeddy, J. (2021). Perbedaan Keparahan Karies Gigi Molar Pertama Pada Anak Usia 6-9 Tahun Dengan 10-12 Tahun: Kajian Pada Radiograf Panoramik Di Rsgm-P Fkg Universitas Trisakti Periode 2017-2019 (Laporan Penelitian). *Jurnal Kedokteran Gigi Terpadu*, 3(1).
3. Amin, M. N., & Permatasari, N. (2017). Aspek biologis pergerakan gigi secara ortodonsi. *Stomatognatic-Jurnal Kedokteran Gigi*, 13(1), 22-27.
4. Mangkat Y, Wowor VNS, Mayulu N. Pola kehilangan gigi pada masyarakat Desa Roong Kecamatan Tondano Barat Minahasa Induk. *e-Gigi J Ilmiah Ked Gi*. 2015;3(2):508-14. DOI: [10.35790/eg.3.2.2015.10015](https://doi.org/10.35790/eg.3.2.2015.10015)
5. Prawesthi, E., & Handayani, S. (2023). Pembuatan Mahkota Tiruan All Zirconia Multilayered CAD/CAM Pada Pasien Dengan Dukungan Gigi Implan Tipe Endosseus (Laporan Kasus). *Jurnal Ilmiah dan Teknologi Kedokteran Gigi*, 19(2), 86-92.
6. Redi Y. (2019). Prosedur Pembuatan Gigi Tiruan Jacket Crown All Acrylic Pada Gigi 11 Dan 21 Dengan Gigi Tiruan Sebagian Lepas Saddle Acrylic Pada Gigi 25. *Repos Poltekkes Tanjungkarang*;4-22.
7. Tiku, Y. G. S., & Jubhari, E. H. (2019). Selection of pontic design. *Makassar Dental Journal*, 8(3).
8. Rosenstiel, S. F., Martin, F. L., & Junhei, F. 2016. *Contemporary Fixed Prosthodontics*. Fifth Edition. Elsevier: Missouri.

9. Bukhari, M., Aldossari, A., & Alyami, I. (2022). Pontic design and its effects on the health of the gingiva. *International Journal of Community Medicine And Public Health*, 9, 4725. DOI: [10.18203/2394-6040.ijcmph20223238](https://doi.org/10.18203/2394-6040.ijcmph20223238)
10. Rosenstiel S. F., Martin, F. L., & Waite R. D., 2023. *Contemporary Fixed Prosthodontics*, Sixth Edition. Elsevier, Philadelphia.
11. Kusdarjanti, E., Setyowati, O., & Zseni, F. (2019). Making Single Complete Dentures for the Material with Tuber Maxilla Case Large. *Journal of Vocational Health Studies*, 3(1), 37-39. DOI: 10.20473/jvhs.V3.I1.2019.37-39
12. Sofya, P. A. (2022). Tingkat Pengetahuan Mahasiswa Program Studi Pendidikan Dokter Terhadap Gigi Tiruan Jembatan. *Jurnal Ilmiah Teknologi Kedokteran Gigi*, 18(1).
13. Panjaitan, E. F., Paramakirana, H., Santosa, P., & Rinastiti, M. (2022). Perawatan Ekstrusi Dan Luksasi Gigi Molar Satu Mandibula Dengan Restorasi Endocrown Fiber Reinforced Composite. *Jurnal Kedokteran Gigi Universitas Padjajaran*, (3):28-36. DOI: [10.24198/jkg.v33i3.33250](https://doi.org/10.24198/jkg.v33i3.33250)
14. Arafah, C. N. H., Shofiyah, N., Wasyim, A. H. P., Maharani, A. K., Kintami, T. G., Hardita, A., ... & Ramadhani, V. (2024). Perawatan Gigi Tiruan Jembatan dengan Sanitary Pontic. *STOMATOGNATIC-Jurnal Kedokteran Gigi*, 21(2), 171-175.
15. Sinamo, S., Caesarina, D., Maghfira, V., & Halim, S. (2022). Laporan Kasus: Gigi Tiruan Cekat. *Prima Journal of Oral and Dental Sciences*, 5(1), 63-68. DOI: [10.34012/primajods.v5i1.2879](https://doi.org/10.34012/primajods.v5i1.2879)
16. Oswal, MansiManish & Oswal, ManishSohan. (2016). Unconventional pontics in fixed partial dentures. *Journal of Dental and Allied Sciences*. 5. 84. 10.4103/2277-4696.192970.
17. Kazmi SMR, Iqbal Z, Muneer MU, Riaz S, Zafar MS. Different pontic design for porcelain fused to metal fixed dental prosthesis: Contemporary guidelines and practice by general dental practitioners. *Eur J Dent*. 2018;12(3):375-379. doi:10.4103/ejd.ejd\_232\_18
18. Binhuraib, H. M., Alqarni, S. S., Mohsen, N. M., Alharbi, A. A., Alghamdi, A. I., Almotairi, A. M., Alhussain, A. H., Felemban, R. A., Alzahrani, A. S., Eyouni, E. S. and Alhajjaji, R. I. (2024) "Long-term maintenance and complications of fixed dental prostheses", *International Journal Of Community Medicine And Public Health*, 11(2), pp. 977–981. doi: 10.18203/2394-6040.ijcmph20240019.